

RESEARCH

Open Access



Is the routine use of a water-soluble contrast enema prior to closure of a loop ileostomy necessary? A review of a single institution experience

Nikoletta Dimitriou^{1,2*}, Sofoklis Panteleimonitis¹, Ajit Dhillon¹, Kirsten Boyle¹, Mike Norwood¹, David Hemingway¹, Justin Yeung¹ and Andrew Miller¹

Abstract

Background: The aims of the study were to determine the radiological leak rate in those patients who had undergone a resection for left-sided colorectal cancer and to see if the presence of a leak can be related with the postoperative clinical period. We also aimed to identify any common factors between patients with leak.

Methods: A retrospective analysis of prospectively collected data of all patients who underwent a left-sided colorectal cancer resection with formation of a defunctioning ileostomy was undertaken. Between 2005 and 2010, 418 such patients were identified.

Results: A water-soluble contrast enema was performed in 339 patients (81.1 %). Of these, 24 (7.1 %) were reported to show an anastomotic leak. Data for these 24 patients is presented in this study. Twenty-three (95.8 %) of the leaks occurred in patients who had undergone an anterior resection; 95.8 % of the patients with a leak were male. Fifteen (62.5 %) patients underwent neo-adjuvant radiation. The mean length of stay in those patients shown to have a subsequent radiological leak was 18.8 days (median), compared with the overall unit figures of 12 days. Only 29.2 % of the patients who had a leak identified had an uncomplicated postoperative period. Overall 87.5 % of the patients had a reversal of the ileostomy.

Conclusions: Radiological leakage is not uncommon. The majority of patients, who were shown to have a radiological leak in this study, were male, had undergone an anterior resection, had received neo-adjuvant radiation, had a longer initial length of stay and had postoperative complications. Water-soluble contrast enemas could be selectively used in patients with these characteristics.

Keywords: Anastomotic leakage, Water-soluble contrast enema, Colorectal cancer

Background

Anastomotic failure following a colorectal resection is a devastating complication for both the patient and surgeon. It is associated with increased morbidity and mortality [1, 2]. Mortality rates are reported to be between 6 and 22 % [3]. The Association of Coloproctology of Great Britain and Ireland Guidelines recommend that the audited leak rate for anterior resections should be below 8 % and below 4 % for all other resections [4]. The

literature reports anastomotic leakage to be between 11 and 12 % after rectal surgery [5, 6] compared with 3–4 % after colonic surgery [7].

The aim of forming a defunctioning loop ileostomy is to divert the faecal stream from the anastomosis. The role of diverting the faecal stream from the anastomosis is still controversial. In a recent meta-analysis of four randomized controlled trials, Huser et al. showed a statistically significant increase in clinical anastomotic leakage and the need for reoperation in patients without a proximal stoma after low anterior resection for cancer [8]. The same results were reported in a Cochrane

* Correspondence: nicdem_gr@hotmail.com

¹Colorectal Department, Leicester Royal Infirmary, Leicester, UK

²26, Mikras Asias str, Athens 11527, Greece

review [9]. Others have argued that the stoma mitigates the consequences of a leakage but does not lower the leakage rate itself, as was the result in a large retrospective multicenter study by Gastinger et al., in which leakage rate was 14 % with and without a defunctioning stoma [10]. A more recent randomized multicentre study concluded that the presence of a defunctioning stoma significantly decreases the rate of symptomatic leakage [11]. A review of almost 2000 patients reported that a defunctioning stoma following a coloanal anastomosis appears to protect against postoperative sepsis, septic shock and need for reoperation; it is overused in patients having a more proximal anastomosis and should be avoided in low-risk patients [12].

Defunctioning loop ileostomies are usually reversed 8–12 weeks from initial surgery [13]. If however, adjuvant chemotherapy is indicated, the time to reversal may be somewhere in the order of 35–40 weeks. In many centres, a water-soluble contrast enema (WSCE) is routinely performed to assess the integrity of the colorectal anastomosis prior to closure. However, such routine practise is controversial. Kalady et al. have shown that a routine WSCE did not reveal any anastomotic leaks that were not already suspected clinically [14]. Jayaraja et al. have also shown that in cases where colonic pouches are formed, the appearances of WSCE can be mistaken for leaks leading to false positive results [15].

The primary aim of our study was to determine the radiological leak rate in those patients who had undergone a resection for left-sided colorectal cancer and to see if the presence of a leak relates with postoperative complications. We also aimed to identify any characteristics in the patients who were identified to have a positive radiological leak. This could help us identify a group of patients who could selectively have a WSCE prior to ileostomy closure.

Methods

A prospective database of all patients with a diagnosis of colorectal cancer has been maintained since 1998 in Leicester. This database was interrogated. A retrospective analysis of all patients who underwent surgery for colorectal cancer with formation of a defunctioning ileostomy over a period of 6 years was performed. Between 2005 and 2010, 418 such patients were identified.

Using our intranet radiology reporting system (IMPAX, AGFA Healthcare N.V., Mortsel, Belgium), we reviewed all 418 patients' radiology records and identified those who had a WSCE following their resection. All WSCE were reported by a consultant GI radiologist. If the results were in doubt, the images were discussed together with the colorectal team consultants. We reviewed all of the medical notes of those patients with a positive radiological leak, in order

to identify any postoperative complications. Data was recorded using a pro forma specifically designed for this study.

Results

Four hundred eighteen patients underwent resectional surgery with formation of a defunctioning loop ileostomy. Of these, 339 (81.1 %) had a WSCE. Out of these 339, 24 (7.1 %) were reported to show an anastomotic leak. Twenty-three (95.8 %) of the leaks occurred in patients who had undergone an anterior resection, of which there were 307. This equates to an overall leak rate of 7.5 % in the anterior resection group.

In the leakage group, 23 patients were male and the median age was 64 years. We obtained the notes for all 24 patients.

We present the data retrieved from the medical records of these 24 patients. Patient characteristics and clinical outcome are presented in Table 1.

Twenty patients had a rectal tumour, three a sigmoid tumour and one a rectosigmoid tumour. The tumour location varied from 5 to 20 cm from the anal verge.

Medical case note review revealed that 5 patients were on aspirin and 1 patient was on steroids preoperatively. Three patients were current smokers; 10 were ex-smokers. Only 6 patients exceeded the recommended weekly alcohol consumption limit (>21 units). Six patients had an ASA score of 3, and the rest of the group had an ASA score of 2. BMI range was between 23 to 34, 8 patients had a BMI between 20–25, 8 between 26–30 and 8 between 31–35. All patients had a normal albumin preoperatively, but 78 % had a low albumin postoperatively.

In total, 15 of the patients (62.5 %) received neo-adjuvant treatment. Eight of those had combined neo-adjuvant chemoradiation, and 7 had only neo-adjuvant radiotherapy. Eight patients subsequently received adjuvant chemotherapy, and 3 received adjuvant chemoradiation. Neo-adjuvant treatment consists of short course radiotherapy (25 Gy) for T2/T3a, N0 rectal cancer and neo-adjuvant chemoradiotherapy with capecitabine, oxaliplatin or 5 fluorouracil, and the radiotherapy dosage is 45–50.4 Gy for locally advanced rectal cancer.

The mean length of stay in those patients showed to have a subsequent radiological leak was 18.8 days. This exceeded the overall unit figure of 12 days. Looking at this in more detail, 23 out of 24 patients stayed over 1 week, 12 out of 24 patients were still an inpatient after 2 weeks and 4 out of 20 patients were still an inpatient after 1 month. An enhanced recovery programme was introduced universally to the colorectal unit in 2010.

Only seven (29.2 %) of these patients had no immediate postoperative complications. Nine (37.5 %) patients developed a postoperative collection or leak, confirmed by CT scan. Two of these patients required intensive

Table 1 Patients characteristics and clinical outcome

| | Gender | Age | Cancer site | Comorbidities | BMI | Smoking | Alcohol U/week | ASA | Neo-adjuvant therapy | Complications | Length of hospital stay |
|----|--------|-----|-----------------------|-----------------------|-----|-----------|----------------|-----|----------------------|--|-------------------------|
| 1 | Male | 73 | Sigmoid | HTN, CHD, CKD Stage 4 | 29 | N | 15 | 3 | N | – | 18 |
| 2 | Male | 55 | Rectum | – | 31 | N | 22 | 2 | Y | Pelvic collection on CT | 40 |
| 3 | Male | 50 | Rectum | – | 32 | N | 4 | 2 | Y | Pelvic collection, on CT | 10 |
| 4 | Male | 62 | Rectum | HTN | 29 | Ex smoker | 28 | 2 | Y | – | 14 |
| 5 | Male | 66 | Rectum | NIDDM, CHD, HTN | 31 | Ex smoker | – | 3 | Y | Ileus | 15 |
| 6 | Male | 68 | Rectum | – | 25 | Ex smoker | 28 | 2 | Only radiation | Wound dehiscence, pelvic collections-EUA, wash out | 38 |
| 7 | Male | 77 | Rectum | CHD | 25 | No | 2 | 3 | Y | Pelvic collection on CT, AF | 23 |
| 8 | Male | 72 | Rectum | – | 29 | Ex smoker | 1 | 2 | N | – | 9 |
| 9 | Male | 75 | Rectum | – | 24 | Ex smoker | – | 2 | N | – | 12 |
| 10 | Male | 66 | Rectosigmoid junction | – | 24 | N | NR | 2 | N | – | 9 |
| 11 | Male | 52 | Rectum | – | 23 | Y | 2 | 2 | Y | Pneumonia | 14 |
| 12 | Male | 62 | Rectum | – | 28 | Ex smoker | 30 | 2 | N | Pneumonia, ileus | 27 |
| 13 | Female | 65 | Sigmoid | – | 23 | N | 1.5 | 2 | N | Obstructed stoma | 25 |
| 14 | Male | 46 | Rectum | – | 33 | N | 1 | 2 | N | Pelvic collection-EUA, washout | 8 |
| 15 | Male | 62 | Rectum | – | 24 | Y | 20 | 2 | Only radiation | Pelvic collection-EUA, washout | 47 |
| 16 | Male | 81 | Rectum | COPD | 32 | Ex smoker | 6 | 3 | N | Pneumonia | 18 |
| 17 | Male | 49 | Rectum | HTN, CHD | 34 | Ex smoker | 20 | 2 | Only radiation | Pelvic collection-EUA, washout | 12 |
| 18 | Male | 59 | Rectum | – | 27 | Ex smoker | 3 | 2 | Y | – | 5 |
| 19 | Male | 70 | Rectum | HTN | 33 | N | 12 | 2 | N | Pelvic collection on CT | 44 |
| 20 | Male | 80 | Rectum | CKD STAGE 3 | 24 | N | 1 | 3 | Only radiation | Pneumonia, AF | 21 |
| 21 | Male | 59 | Rectum | HTN | 28 | Y | 35 | 2 | Only radiation | AF | 9 |
| 22 | Male | 65 | Rectum | CHD, COPD | 30 | Ex smoker | 15 | 2 | Only radiation | Pelvic collection—USS-guided drainage | 12 |
| 23 | Male | 54 | Rectum | – | 33 | N | 32 | 2 | Y | – | 5 |
| 24 | Male | 68 | Sigmoid | HTN, MI | 28 | N | 10 | 3 | Only radiation | UTI, ileus | 16 |

HTN hypertension, NIDDM noninsulin-dependent diabetes mellitus, AF atrial fibrillation, CKD chronic kidney disease, UTI urinary tract infection, CHD coronary heart disease, COPD chronic obstructive pulmonary disease, NR not reported, EUA examination under anaesthesia, Y yes, N no, U units, USS ultrasound

treatment unit admission. Patients with collection had a drainage either radiologically or transanally in theatre. Four patients developed postoperative ileus that resolved with conservative therapy, and two patients developed AF. Mean time from ileostomy formation to WSCE was 93.6 days.

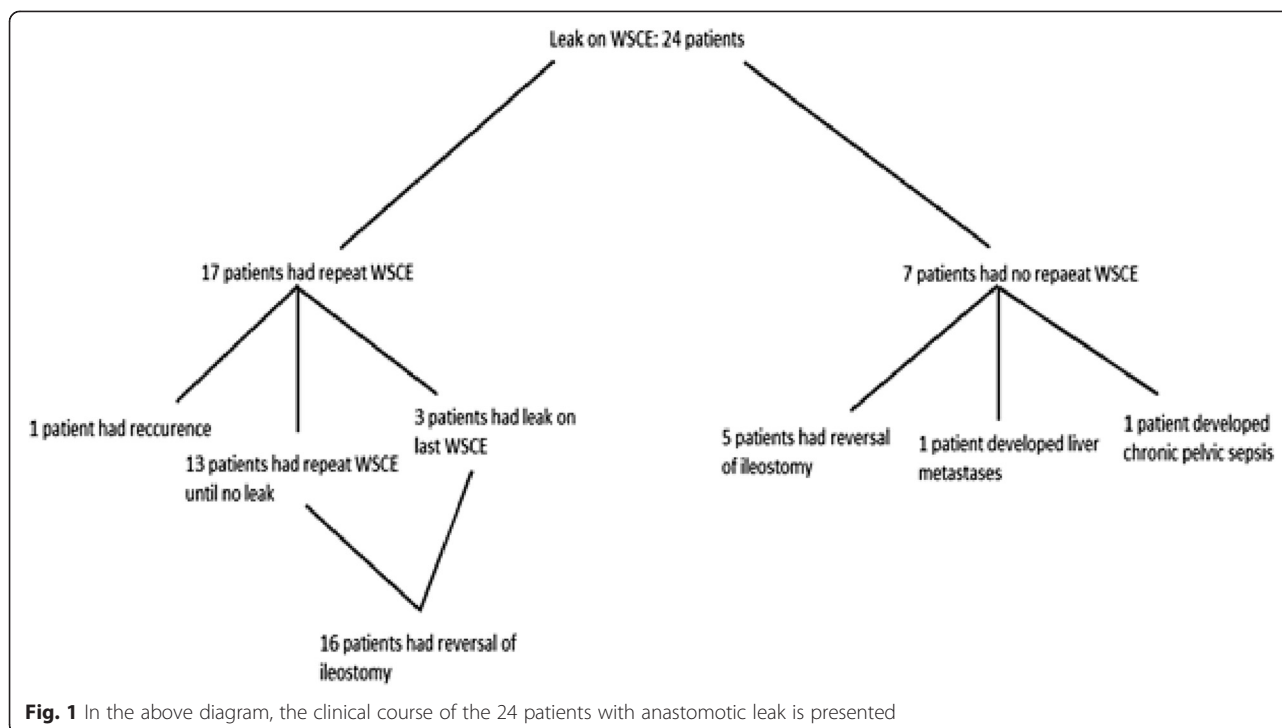
Following identification of a positive radiological leak on WSCE, 17 patients underwent a subsequent WSCE; however, 7 did not have a subsequent WSCE. Of the 17 who had a repeat WSCE, 13 had further repeat WSCEs until no leak was identified and thereafter underwent ileostomy reversal. Three patients were found to have a positive radiological leak on their last WSCE but had their ileostomy reversed, more than 12 months from their original surgery. One of those patients

subsequently found to have a local recurrence and required further surgical treatment.

Of the seven who did not have repeat WSCEs, five had their ileostomy reversed uneventfully, 1 patient was found to have liver metastases and did not wish to have his ileostomy reversed and 1 developed chronic pelvic sepsis and did not have reversal of his ileostomy.

However, of greater interest, seven patients underwent ileostomy closure despite their last WSCE being positive for a radiological leak. All seven patients made an uneventful recovery, but one developed recurrence at the anastomosis site. In Fig. 1, the clinical course of the 24 patients with anastomotic leak is presented.

In summary the leak rate discovered in WSCE was 7.1 %. Twenty-three out of 24 patients had an anterior



resection, and 95.8 % of the patients were male. Of these patients, 62.5 % had neo-adjuvant radiotherapy. Only 29.2 % of the patients had an uncomplicated postoperative period. The mean hospital stay was 18.8 days, higher than the overall hospital stay of the unit. Finally, 87.5 % of the patients had a reversal of the ileostomy.

Discussion

A defunctioning stoma is frequently created to minimize the impact of any subsequent anastomotic leak after a low rectal anastomosis [16].

Water-soluble contrast enemas (WSCEs) are used to assess the integrity of the anastomosis before the loop ileostomies are reversed and normal faecal stream resumes. But the routine use of WSCE is still controversial; studies have shown that WSCE fails to provide any additional information that result in a change to patient management [14, 17].

Our overall radiological leak rate was 7.1 %. The majority of patients who found to have radiological leaks had common characteristics. An anterior resection was the operation performed in 95.8 % patients with a radiological leak. In the group as a whole, 80 % of patients underwent an anterior resection. Moreover, 95.8 % of the patients were male. Of the patients who had a radiological leak, 62.5 % had neo-adjuvant radiation and 45.8 % had adjuvant chemotherapy. Our findings agree with a recent systematic review and meta-analysis that showed that anterior resection, male gender and neo-

adjuvant radiotherapy are risk factors for anastomotic leakage [18].

Furthermore, it was found that the length of stay of the patients who had a radiological leak was higher than the overall unit figures (mean 18.8 vs 12). Only 29.2 % of the patients with leak had an uncomplicated postoperative period. Of the patients, 37.5 % had clinical leak confirm postoperatively with CT scan. Our data confirms a previous study that reports that all anastomotic leaks were diagnosed clinically and WSCE did not provide any additional information [19].

Thirteen (54.2 %) of our patients who had positive radiological leaks had repeat WSCEs until they had a negative WSCE before reversing the loop ileostomy. Seven patients (33.3 %) who had their ileostomies reversed whilst their last WSCE showed a radiological leak. All of these seven patients were more than 12 months from ileostomy formation and all made an uneventful recovery, but one went on to develop an anastomotic recurrence. This could indicate two things: either the time frame from the last WSCE to reversal was enough to allow the leaks to resolve or if the patients are clinically well and anastomotic leak on WSCE is not a contraindication for reversal.

In a previous study of 174 patients, 6.4 % of WSCEs showed pathology but had normal digital rectal examinations [20]. These patients had their ileostomies reversed with no subsequent complications. It is not surprising that they have suggested digital rectal examination as a more reliable alternative to WSCE. However,

this is solely dependent on the experience of the performing surgeon. In another similar study, digital rectal examination and rigid proctoscopy were shown to have equal sensitivity as WSCE (100 %) [17]. The authors suggest that routine digital rectal examination and rigid proctoscopy can be used to evaluate low pelvic anastomosis, and WSCE should be used only on selective cases with abnormal findings [17].

Conclusions

Overall, radiological leakage is uncommon. An anastomotic leak is usually clinically recognized and should always be considered in any patient who is unwell in the postoperative period. However, the majority of patients who do have a leak have undergone anterior resections and are male, have neo-adjuvant radiation and have a longer initial length of stay and have postoperative complications, either a cardiac event, fever, or post operative ileus. These characteristics could form the basis of a selective policy for the use of WSCE.

Competing interests

The authors declare that they have no competing interests.

Authors' contributions

ND participated in the design of the study, collected the data, analysed data and drafted the manuscript. SP participated in the design of the study, collected the data and drafted the manuscript. AD collected the data. KB participated in the design of the study and drafted the manuscript. MN conceived of the study and revised the manuscript. DH conceived of the study, participated in its design and coordination and revised the manuscript. JY conceived of the study, participated in its design and coordination and revised the manuscript. AM conceived of the study, participated in its design and coordination and revised the manuscript. All authors read and approved the final manuscript.

Received: 13 June 2015 Accepted: 26 November 2015

Published online: 04 December 2015

References

- Hyman NH, Osler T, Cataldo P, Burns EH, Shackford SR. Anastomotic leaks after bowel resection: what does peer review teach us about the relationship to postoperative mortality? *J Am Coll Surg*. 2009;208(1):48–52.
- Rullier E, Laurent C, Garrelon JL, Michel P, Saric J, Parnet M. Risk factors for anastomotic leakage after resection of rectal cancer. *Br J Surg*. 1998;85(3):355–8.
- Ajani JA. In rectal carcinoma, colostomy or no colostomy: is this the question? *J Clin Oncol*. 1993;11(1):193–4.
- Association of Coloproctology of Great Britain and Ireland. Guidelines for the management of colorectal cancer 3rd edition. 2007. <http://www.acpghi.org.uk/assets/documents/resources/guidelines/guidelines-for-the-management-of-colorectal-cancer>.
- Peeters KC, Tollenaar RA, Marijnen CA, Klein Kranenburg E, Setup WH, Wiggers T, et al. Risk factors for anastomotic failure after total mesorectal excision of rectal cancer. *Br J Surg*. 2005;92(2):211–6.
- Bertelsen CA, Andreasen AH, Jorgensen T, Harling H. Anastomotic leakage after anterior resection for rectal cancer: risk factors. *Colorectal Dis*. 2010;12(1):37–43.
- Kube R, Mroczkowski P, Granoski D, Benedix F, Sahn M, Schmidt U, et al. Anastomotic leakage after colon cancer surgery: a predictor of significant morbidity and hospital mortality, and diminished tumour-free survival. *Eur J Surg Oncol*. 2010;36(2):120–4.
- Huser N, Michalski CW, Erkan M, Schuster T, Rosenberg R, Kleeff J, et al. Systematic review and meta-analysis of the role of defunctioning stoma in low rectal cancer surgery. *Ann Surg*. 2008;248:52–60.
- Montedori A, Cirocchi R, Farinella E, Sciannone F, Abraha I. Covering ileo- or colostomy in anterior resection for rectal carcinoma. *Cochrane Database Syst Rev*. 2010;5:CD006878.
- Gastinger I, Marusch F, Steinert R, Wolff S, Koeckerling F, Lippert H. Protective defunctioning stoma in low anterior resection for rectal carcinoma. *Br J Surg*. 2005;92:1137–42.
- Matthiessen P, Hallböök O, Rutegård J, Simert G, Sjö Dahl R. Defunctioning stoma reduces symptomatic anastomotic leakage after low anterior resection of the rectum for cancer: a randomized multicenter trial. *Ann Surg*. 2007;246:207–14.
- Nurkin S, Kakarla VR, Ruiz DE, Cance WG, Tiszenkel HI. The role of faecal diversion in low rectal cancer: a review of 1791 patients having rectal resection with anastomosis for cancer, with and without a proximal stoma. *Colorectal Dis*. 2013;15(6):309–16.
- Khair G, Alhamarneh O, Avery J, Cast J, Gunn J, Monson JR, et al. Routine use of gastrografin enema prior to the reversal of a loop ileostomy. *Dig Surg*. 2007;24(5):338–41.
- Kalady MF, Mantyh CR, Petrofski J, Ludwig KA. Routine contrast imaging of low pelvic anastomosis prior to closure of defunctioning ileostomy: is it necessary? *J Gastrointest Surg*. 2008;12(7):1227–31.
- Jeyarajah S, Sutton C, Miller A, Hemingway D. Colo-anal pouches: lessons from a prospective audit. *Colorectal Dis*. 2008;10(6):599–604.
- Tan WS, Tang CL, Shi L, Eu KW. Meta-analysis of defunctioning stomas in low anterior resection for rectal cancer. *Br J Surg*. 2009;96(5):462–72.
- Karsten BJ, King JB, Kumar RR. Role of water-soluble enema before takedown of diverting ileostomy for low pelvic anastomosis. *Am Surg*. 2009;75(10):941–4.
- Pommergaard HC, Gessler B, Burcharth J, Angenete E, Haglund E, Rosenberg J. Preoperative risk factors for anastomotic leakage after resection for colorectal cancer: a systematic review and meta-analysis. *Colorectal Dis*. 2014;16(9):662–71.
- Hong SY, Kim do Y, Oh SY, Suh KW. Routine barium enema prior to closure of defunctioning ileostomy is not necessary. *J Korean Surg Soc*. 2012;83(2):88–91.
- Tang CL, Seow-Choen F. Digital rectal examination compares favourably with conventional water-soluble contrast enema in the assessment of anastomotic healing after low rectal excision: a cohort study. *Int J Colorectal Dis*. 2005;20(3):262–6.

Submit your next manuscript to BioMed Central and we will help you at every step:

- We accept pre-submission inquiries
- Our selector tool helps you to find the most relevant journal
- We provide round the clock customer support
- Convenient online submission
- Thorough peer review
- Inclusion in PubMed and all major indexing services
- Maximum visibility for your research

Submit your manuscript at
www.biomedcentral.com/submit

