

## Case report

## Open Access

### Multiple rectal carcinoids with diffuse ganglioneuromatosis

Masashi Haraguchi\*<sup>1,4</sup>, Hideki Kinoshita<sup>2</sup>, Miho Koori<sup>1</sup>,  
Noritsugu Tsuneoka<sup>1</sup>, Taiichiro Kosaka<sup>1</sup>, Yuji Ito<sup>3</sup>, Junichiro Furui<sup>1</sup> and  
Takashi Kanematsu<sup>4</sup>

Address: <sup>1</sup>Department of Surgery, Goto Central Hospital, Nagasaki, Japan, <sup>2</sup>Department of Internal Medicine, Goto Central Hospital, Nagasaki, Japan, <sup>3</sup>Department of Pathology, SRL Nishi-nihon, Japan and <sup>4</sup>Department of Surgery, Graduate School of Biomedical Sciences, Nagasaki University, Japan

Email: Masashi Haraguchi\* - haraguchi@mb.ejnet.ne.jp; Hideki Kinoshita - onagagre@bf.mbn.or.jp;  
Miho Koori - mihomihochang@hotmail.co.jp; Noritsugu Tsuneoka - noritugu@xd5.so-net.ne.jp;  
Taiichiro Kosaka - taiichiro1111@hotmail.com; Yuji Ito - uzitoh-wsrl@srl.srl-inc.co.jp; Junichiro Furui - furui@vc.fctv-net.jp;  
Takashi Kanematsu - kanematsu@net.nagasaki-u.ac.jp

\* Corresponding author

Published: 16 February 2007

Received: 19 October 2006

Accepted: 16 February 2007

World Journal of Surgical Oncology 2007, 5:19 doi:10.1186/1477-7819-5-19

This article is available from: <http://www.wjso.com/content/5/1/19>

© 2007 Haraguchi et al; licensee BioMed Central Ltd.

This is an Open Access article distributed under the terms of the Creative Commons Attribution License (<http://creativecommons.org/licenses/by/2.0>), which permits unrestricted use, distribution, and reproduction in any medium, provided the original work is properly cited.

## Abstract

**Background:** Rectal carcinoids comprise only about 1% of all anorectal neoplasms. In addition, ganglioneuroma of the gastrointestinal tract is a rare tumor composed ganglion cells, nerve fibers, and supporting cells. Multiple carcinoid tumors with diffuse ganglioneuromatosis limited to the rectum are quite unusual.

**Case presentation:** A 69-year-old man was referred to us because of about 100 small submucosal rectal tumors. He underwent abdominoperineal resection. Pathology revealed carcinoid tumors for about 30 submucosal nodules and diffuse ganglioneuromatosis. To date (6 months later) he remains well with no recurrence.

**Conclusion:** Although the optimal treatment for the multiple rectal carcinoids remains to be clearly established, it is believed that not all patients with multiple rectal carcinoids (measuring less than 1 cm in diameter) need to have a radical operation. However, the treatment plan for each case should be individualized and a careful follow-up is mandatory.

## Background

Carcinoid tumors were initially described as a morphologically distinct subset of small intestinal neoplasms with a less aggressive behavior than that of the intestinal adenocarcinoma. Carcinoid tumors of the rectum comprise only about 1% of all anorectal neoplasms [1]. Typi-

cally, rectal carcinoids present as small, solitary submucosal nodules. Multicentricity is an even more rare occurrence. Only 33 patients with multiple rectal carcinoids, including our patient, have so far been reported in Japan [2].

Gastrointestinal ganglioneuromas are also rare tumors that are generally well differentiated and benign tumors. They commonly occur in the retroperitoneum and posterior mediastinum. Though they may be found anywhere in the body, particularly in the distribution of the major sympathetic ganglia, their involvement in the gastrointestinal tract is a rare occurrence. Some reports have indicated that ganglioneuromas of the gastrointestinal tract have been found in patients with several systemic disorders including multiple endocrine neoplasia IIB (MEN IIB), von Recklinghausen's disease, tuberous sclerosis, Cowden's disease, juvenile polyposis, filiform polyposis, and colonic adenocarcinoma [3,4].

Multiple carcinoid tumors with diffuse ganglioneuromatosis limited to the rectum are quite unusual. The relationship between multiple carcinoid tumors and gastrointestinal ganglioneuromatosis of the rectum is herein discussed.

### Case presentation

A 69-year-old man was referred to us because of about 100 small submucosal rectal tumors detected at examination by his private physician. Multiple biopsies reported to be a tentative diagnosis of multiple carcinoid tumors. He had never been diagnosed as having multiple endocrine neoplasia (MEN) or other multiple tumor syndromes. His family history was not contributory. Physical examination revealed no abnormalities. Serum serotonin level was within normal range, 221 ng/ml. Tumor markers were within normal limits, CEA (carcinoembryonic antigen) 2.3 ng/ml, CA (carbohydrate antigen) 19-9 <2.0 U/ml. Computed tomographs of the brain, chest, abdomen and pelvis did not show any abnormality. He underwent abdominoperineal resection. Pathology revealed carcinoid tumors for about 30 submucosal nodules, which especially concentrated in the lower rectum (Figure 1a-c, Figure 2a,b) and diffuse ganglioneuromatosis (Figure 3a,b). Both carcinoid tumors and ganglioneuroma located within the mucosal and submucosal layer. There was neither metastasis to the liver nor the lymph node. The patient had an uneventful recovery and is maintaining good health at 6 months after surgery at this writing.

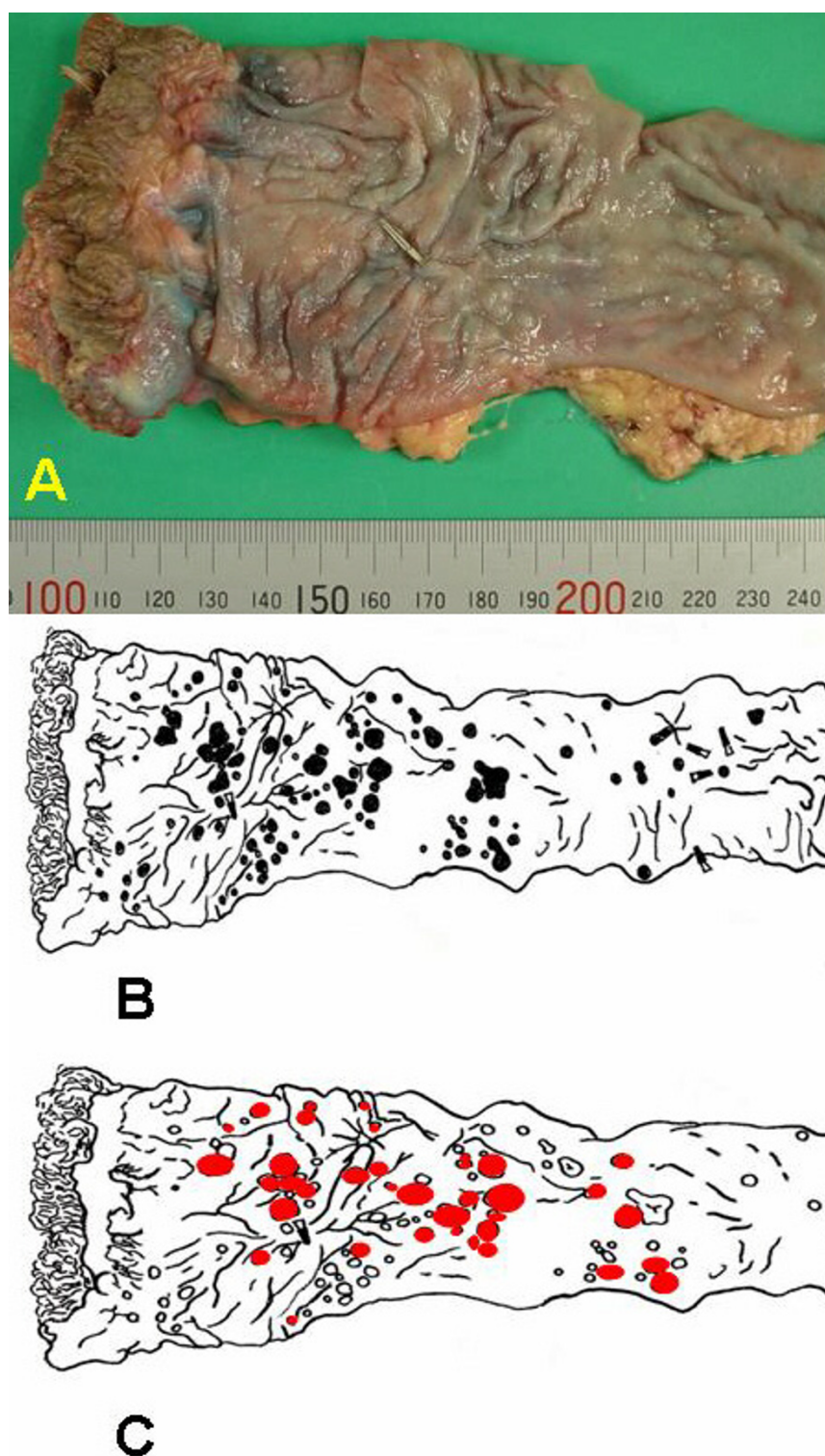
### Discussion

Carcinoid tumors of the rectum are considered to be a frequent primary site [5]. One-half of all rectal carcinoids are discovered during anorectal examinations in asymptomatic patients. The remainders are found primarily by examinations of patients for symptoms (bleeding, constipation, rectal pain and so on). They are discovered most frequently in the 5th and 6th decades of life, with an equal gender distribution. Rectal carcinoid tumors usually occur singly, and the reported incidence of multiple carcinoid tumors is only 2% to 4.5% [6].

On the other hand, gastrointestinal ganglioneuromas may be classified into three major categories: diffuse ganglioneuromatosis, ganglioneuromatous polyposis, and polypoid ganglioneuromas [4]. Diffuse ganglioneuromatosis is a poorly demarcated nodular and diffuse intramural or transmural proliferation of ganglioneuromatous tissue elements involving the enteric plexuses. Transmural ganglioneuromatosis with the involvement of the myenteric plexus predominates in individuals with multiple endocrine neoplasia IIB (MEN IIB), whereas the involvement limited to the mucosa characterizes the disease in von Recklinghausen's disease [3]. Colonic adenocarcinoma has been described in association with diffuse ganglioneuromatosis and ganglioneuromatous polyposis in a small number of cases [3]. However, no association with MEN IIB, von Recklinghausen's disease and adenocarcinoma has been observed in our patient. Localized gastrointestinal ganglioneuromatosis produces no characteristic symptoms and they are noted incidentally at endoscopy, surgery, or autopsy. Abdominal pain, obstruction, constipation, ileus, weight loss, and appendicitis are all considered to be related to the location and extent of the tumors. In our patient, gastrointestinal ganglioneuromatosis was not diagnosed before the operation.

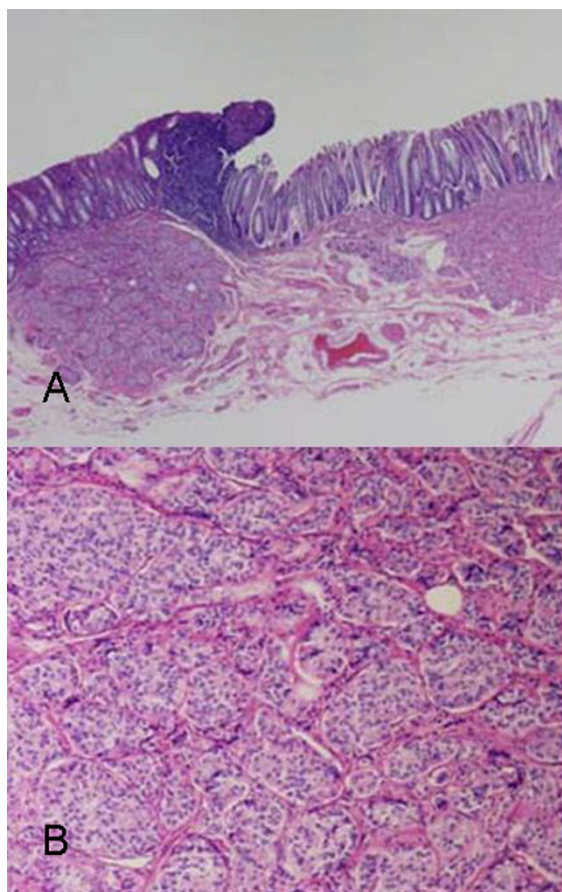
Carcinoid tumors have been reported to be part of hereditary cancer syndrome [7]. The most common association is with the multiple endocrine neoplasia (MEN) syndrome. Although gastrointestinal ganglioneuromas have been especially reported to be associated with MEN IIB, carcinoid tumors are more frequently associated with MEN I [7]. Carcinoid and ganglioneuroma are both indicative of an overlapping syndrome of common neuroendocrine origin [8]. Patients with carcinoid tumors and ganglioneuromatosis should therefore be carefully observed for further manifestations of MEN syndrome.

The surgical treatment for carcinoid tumors is generally dictated to a degree, but not absolutely, by the size [1]. Tumors less than 1 cm in diameter are rarely associated with metastatic disease. Tumors measuring from 1.0 to 1.9 cm in diameter tend to show metastases in 10% of all cases. Lymph node or liver metastases are seen in from 80 to 100% of tumors measuring more than 2 cm in diameter. Rectal carcinoid tumors measuring less than 1 cm are usually treated by local excision including endoscopic techniques. In our case, the sizes of about 30 carcinoid tumors were all less than 1 cm. The treatment of ganglioneuroma also consists of a local excision as these tumors usually exhibit a benign clinical behavior. However, several reports have shown that the incidence of lymph node metastasis is higher (10 to 22.7%) in multiple rectal carcinoid tumors measuring less than 1 cm than in isolated single tumors less than 1 cm [2]. Furthermore, we determined that a resection by an endoscopic operation was

**Figure I**

**a)** Macroscopic findings of the resected rectum demonstrating multiple submucosal tumors. **I.b)** A schematic drawing of the resected rectum showing the location of submucosal tumors (●). **I.c)** A schematic drawing of the resected rectum showing the location of carcinoid tumors (●).



**Figure 2**

**a)** A carcinoid tumor proliferating submucosa **b)** A carcinoid tumor: uniform small round, polygonal prominent round nuclei.

difficult, because preoperatively about 100 submucosal nodules were identified, including carcinoid tumors and ganglioneuromas, in the rectum. As a result, an abdominoperineal resection was performed.

### Conclusion

Although the optimal treatment for the multiple rectal carcinoids remains to be clearly established, it is believed that not all patients with multiple rectal carcinoids (measuring less than 1 cm in diameter) need to have a radical operation. However, the treatment plan for each case should be individualized and a careful follow-up is mandatory.

### Competing interests

The author(s) declare that they have no competing interests.

### Authors' contributions

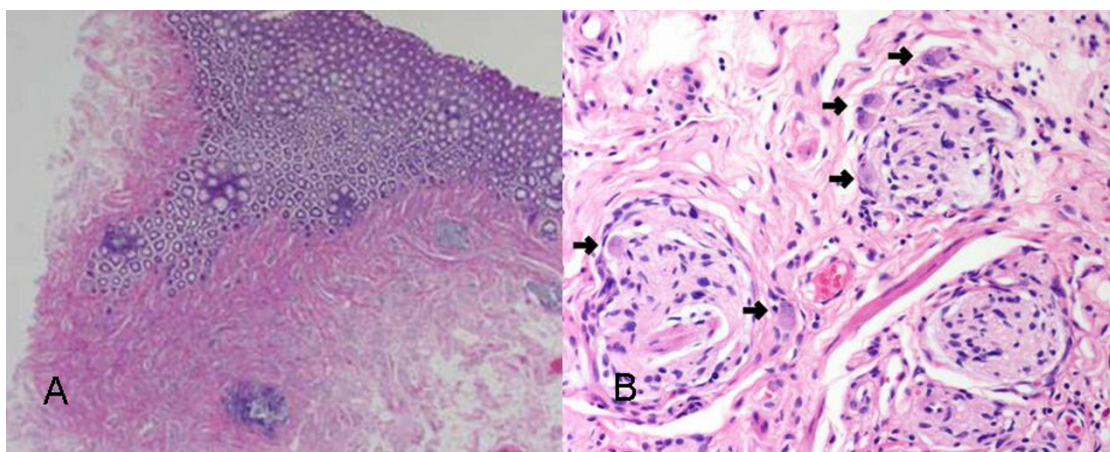
MH, MK, NT, TK and JF carried out the surgical procedures; MH and JF contributed to the design of the study; HK gathered the data from the literature search; YI performed the histological analysis of all surgical specimens and provided histological sections as figures for the manuscript; TK revised and finally approved the manuscript for publication. All authors approved the final manuscript.

### Acknowledgements

Patients consent was obtained for publication of this case report

### References

1. Winburn GB: **Multiple rectal carcinoids: a case report.** *Am Surg* 1998, **64**:1200-1203.
2. Sumida T, Nagata S, Ougoshi H, Ishida Y, Kuwahara T, Tatsugami M, Tsuji K, Hidaka T, Tachiyama Y, Kaneko M, Hayashi Y: **Multiple rec-**

**Figure 3**

**a)** A section of the mucosa and submucosa showing extensive ganglioneuromatosis **b)** A ganglion cell (arrow) is surrounded by spindle cells.

**tal carcinoid tumors treated by endoscopic mucosal resection-Report of a case.** *Gastroenterol Endosc* 2005, **47**:1419-1424. (in Japanese)

3. Rafiq S, Hameer H, Sitrin MD: **Ganglioneuromatous polyposis associated with juvenile polyps and a tubular adenoma.** *Dig Dis Sci* 2005, **50**:506-508.
4. Kanter AS, Hyman NH, Li SC: **Ganglioneuromatous polyposis: a premalignant condition. Report of a case and review of the literature.** *Dis Colon Rectum* 2001, **44**:591-593.
5. Jetmore AB, Ray JE, Gathright JB Jr, McMullen KM, Hicks TC, Timmcke AE: **Rectal carcinoids: the most frequent carcinoid tumor.** *Dis Colon Rectum* 1992, **35**:717-725.
6. Maruyama M, Fukayama M, Koike M: **A case of multiple carcinoid tumors of the rectum with extraglandular endocrine cell proliferation.** *Cancer* 1988, **61**:131-136.
7. Katdare MV, Fichera A, Heilmann TM: **Familial rectal carcinoid: report of two first-degree relatives with rectal carcinoid and review of the literature.** *Tech Coloproctol* 2006, **10**:143-146.
8. Hansen OP, Hansen M, Hansen HH, Rose B: **Multiple endocrine adenomatosis of mixed type.** *Acta Med Scand* 1976, **200**:327-331.

Publish with **BioMed Central** and every scientist can read your work free of charge

"BioMed Central will be the most significant development for disseminating the results of biomedical research in our lifetime."

Sir Paul Nurse, Cancer Research UK

Your research papers will be:

- available free of charge to the entire biomedical community
- peer reviewed and published immediately upon acceptance
- cited in PubMed and archived on PubMed Central
- yours — you keep the copyright

Submit your manuscript here:  
[http://www.biomedcentral.com/info/publishing\\_adv.asp](http://www.biomedcentral.com/info/publishing_adv.asp)

