

Review

Open Access

Aggressive treatment of metastatic squamous cell carcinoma of the rectum to the liver: a case report and a brief review of the literature

Theodosios K Theodosopoulos*¹, Athanasios D Marinis¹,
Nikolaos A Dafnios¹, John G Vassiliou¹, Lazaros D Samanides¹,
Eleni E Carvounis² and Vassilios E Smyrniotis¹

Address: ¹Second Department of Surgery, Areteion University Hospital, Athens Medical School, University of Athens, 76 Vasilisis Sofias av., 11528, Athens, Greece and ²Department of Pathology, Areteion University Hospital, Athens Medical School, University of Athens, 76 Vasilisis Sofias av., 11528, Athens, Greece

Email: Theodosios K Theodosopoulos* - theodosios@panafonet.gr; Athanasios D Marinis - sakisdoc@yahoo.com;
Nikolaos A Dafnios - nickdafnios@in.gr; John G Vassiliou - ianvass@otenet.gr; Lazaros D Samanides - l_samanides@otenet.gr;
Eleni E Carvounis - euthymiou@hol.gr; Vassilios E Smyrniotis - vsmyrniotis@hotmail.com

* Corresponding author

Published: 08 August 2006

Received: 01 May 2006

World Journal of Surgical Oncology 2006, 4:49 doi:10.1186/1477-7819-4-49

Accepted: 08 August 2006

This article is available from: <http://www.wjso.com/content/4/1/49>

© 2006 Theodosopoulos et al; licensee BioMed Central Ltd.

This is an Open Access article distributed under the terms of the Creative Commons Attribution License (<http://creativecommons.org/licenses/by/2.0>), which permits unrestricted use, distribution, and reproduction in any medium, provided the original work is properly cited.

Abstract

Background: Rectal squamous cell carcinoma (SCC) is a rare tumor. The incidence of this malignancy has been reported to be 0.25 to 1 per 1000 colorectal carcinomas. From a review of the English literature 55 cases of SCC of the rectum have been published. In this study we report a rectal metastatic SCC to the liver, discussing the efficacy of aggressive adjuvant and neo-adjuvant therapies on survival and prognosis.

Case presentation: A 39-year-old female patient with a pure SCC of the rectum diagnosed endoscopically is presented. The patient underwent initially neoadjuvant chemo-radiotherapy and then abdominoperineal resection with concomitant bilateral oophorectomy and hysterectomy, followed by adjuvant chemo-radiotherapy. Five months after the initial operation liver metastasis was demonstrated and a liver resection was carried out, followed by adjuvant chemotherapy. Eighteen months after the initial operation the patient is alive.

Conclusion: Although prognosis of rectal SCC is worse than that of adenocarcinoma, an aggressive therapeutic approach with surgery as the primary treatment, followed by combined neo- and adjuvant chemo-radiotherapy, may be necessary in order to improve survival and prognosis.

Background

The squamous cell carcinoma (SCC) of the rectum is a rare tumor with a not yet clarified pathogenesis mechanism and a rather aggressive clinical behavior. It has a slight female predominance and prognosis worse than that of adenocarcinoma. Radical surgery is the cornerstone of treatment. However, the role of chemotherapy

and radiation in the pre- and postoperative period remains to be elucidated. In the present study a case of a metastatic pure SCC of the rectum to the liver is presented. Aggressive surgical treatment as well as combined neoadjuvant and adjuvant chemotherapy and radiation is described, suggesting a possible positive survival and prognostic effect.

Case presentation

A 39-year-old female patient was admitted to our Medical Center's surgical department with a 2 month history of altered bowel habits, perianal pain and rectal bleeding. Colonoscopy demonstrated a circumferentially developing ulcerated tumor 8 cm above the dentate line, extending 4 cm proximally. The colonoscope was advanced past the tumor, performing a total colonoscopy, while biopsies from the lesion were obtained and examined histologically, revealing a non-keratinized squamous cell carcinoma of the rectum. Abdominal computed tomography and chest radiograph were negative for metastatic disease. However, a transanal endoscopic ultrasound demonstrated the spread of the tumor beyond bowel's wall in the perirectal space, necessitating institution of neoadjuvant therapy. The patient underwent 1 session of neoadjuvant chemotherapy with 5-Fluorouracil (1000 mg/m²/d) plus Mitomycin and 5 sessions of radiotherapy (totally 20 Gy). Two days after the last session of radiotherapy a laparotomy was performed. Intraoperative findings included invasion of the posterior vaginal wall from the tumor and an abdominoperineal resection and a concomitant total hysterectomy-oophorectomy were carried out. Histology reported the presence of two ulcerated lesions (1 × 2 cm and 2 × 4 cm) in middle and lower rectum both squamous cell carcinoma of the rectum, invading the bowel wall and the adjacent vaginal wall. The surgical specimen contained 15 lymph nodes, all negative for metastatic disease (T4 N0 M0, stage IIb) and the resected margins were free of tumor. Postoperatively, adjuvant chemotherapy (1 session of 5-FU plus Mitomycin) and 23 sessions of radiotherapy (totally 45 Gy) were administered.

Five months after tumor resection, liver metastasis was demonstrated in a follow-up abdominal computed tomography and a central hepatectomy was performed. Histology confirmed the presence of a metastatic rectal squamous cell carcinoma to the liver (Figure 1, 2). Adjuvant chemotherapy consisting of 6 sessions of 5-FU plus Cisplatin (100 mg/m²/d) was applied. Fortunately, the patient had an uneventful postoperative course and is alive 18 months after.

Discussion

Since the first report of rectal SCC by Raiford in 1933 [1], few cases have been reported in the literature. A PubMed search revealed a total of 55 case reports published since 1943 in the English literature (Table 1). Surprisingly and in contrast to the English reports, a Russian paper in 1984 reviews the clinical manifestations of 107 cases of SCC of the rectum [8].

Rectal SCC is a rare tumor. The incidence of this malignancy has been reported to be 0.25 to 1 per 1000 colorectal carcinomas [4,5,7,21]. In 1979, Williams *et al.* [5]

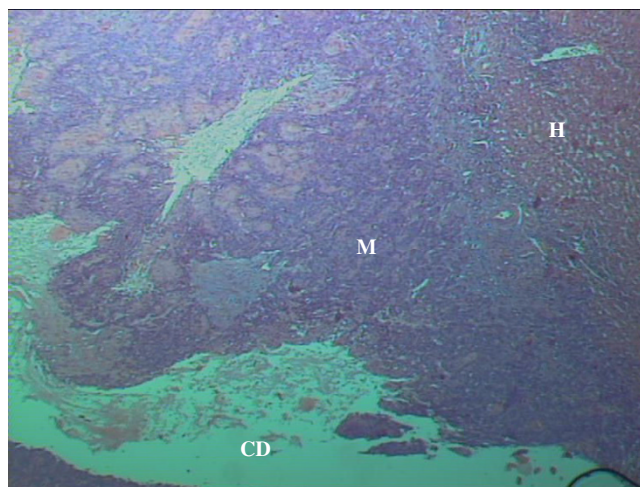


Figure 1
Rectal SCC metastatic to the Liver. The hepatic parenchyma, a metastatic deposit and a cystic degeneration of the tumor are shown (H&E stain, × 25).

described three criteria that are useful today in diagnosing a primary colorectal SCC: first, metastases from other sites (e.g. lung SCC) must be ruled out; second, a squamous-cell-lined fistula must not involve the affected bowel and third, a SCC of the anus extending to the rectum must be excluded.

It seems that the pathogenesis of this malignancy is not yet clear and many theories exist [18-20]: the pluripotent stem cell theory supports that squamous cell carcinomas arise within poorly differentiated tumors [22]; the theory of proliferation of uncommitted basal cells into squa-

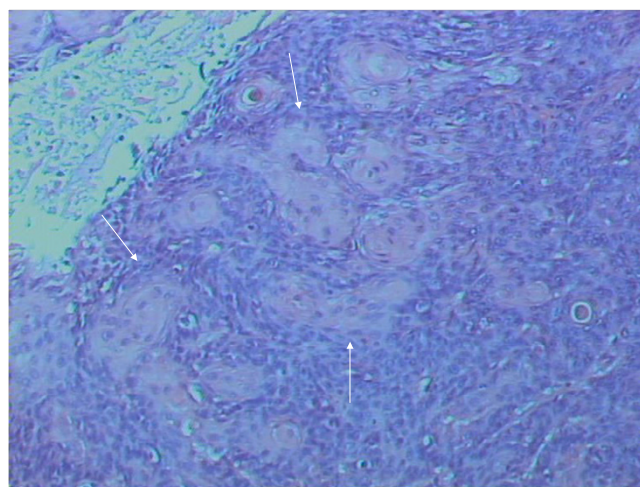


Figure 2
Rectal SCC metastatic to the Liver. A high power view of the tumor, showing squamous differentiation (H&E stain, × 100).

Table 1: Cases of SCC of the rectum reported in the literature.

Author	Date	Age	Gender	Treatment	Outcome
Catell & Williams [2]	1943	63	M	LAR	Alive 3,5 years
Wiener et al [3]	1962	52	F	APR	Died at 1 year
Comer et al [4]	1971	34	F	APR	Alive at 13 years
"		N/A	N/A	N/A	N/A
Williams et al [5]	1979	N/A	N/A	N/A	N/A
Lasser et al [6]	1980	65	F	N/A	Alive at 3 years
"		48	F	N/A	Alive 8 months
"		54	M	N/A	Alive 17 months
Vezeridis et al [7]	1983	56	M	APR	Intraoperative death
"		44	M	APR	Died on 9 po day
"		61	F	CT	Died at 4 months
"		66	F	CT & RT	Died at 15 months
"		62	F	APR	Died at 13 months
Mel'nikov et al [8]	1984			107 CASES REPORTED	
Lafreniere & Ketcham [9]	1985	N/A	N/A	N/A	Alive at 2 years
Piggot & Williams [10]	1987	N/A	N/A	APR	Alive 1 year
Woods [11]	1987	N/A	N/A	N/A	N/A
Singh & Wong [12]	1987	N/A	N/A	N/A	N/A
Prener & Nielsen [13]	1988	N/A	N/A	16 CASES REPORTED	N/A
Schneider et al [14]	1992	43	F	Surgery & RT	Alive 7 months
"		44	M	Surgery & RT	N/A
"		69	F	Surgery & RT	Alive 6 months
Petrelli et al [15]	1996	62	M	APR	-
Martinez et al [16]	1996	40	M	LAR & RT & CT	Alive 18 months
Copur et al [17]	2001	N/A	N/A	APR & CT & RT	N/A
Frizelle et al [18]	2001			9 CASES REPORTED	
Gelas et al [19]	2002	47	F	APR & RT	Alive at 16 years
"		63	M	APR & CT & RT	Died at 14 months
"		70	F	APR & RT	Died at 18 months
"		93	M	RT	Died at 4 months
"		45	F	LAR & CT & RT	Alive at 6 months
"		43	F	LAR & CT & RT	Alive at 2 years
Anagnostopoulos et al [20]	2005	75	M	APR & CT	Alive at 14 months

LAR = Low Anterior Resection; APR = Abdominoperineal Resection; CT = Chemotherapy; RT = Radiation Therapy; F = Female; M = Male ; N/A = not available.

mous cells, which undergo malignant transformation due to chronic injury of the glandular epithelium [23]; the theory of chronic irritation from ulcerative colitis [24], radiation exposure [25] and human papilloma virus [26], resulting in squamous metaplasia of the epithelium; and lastly, the theory of squamous differentiation of adenomas and adenocarcinomas.

Clinical manifestations of SCC of the rectum are similar to those of adenocarcinoma: change in bowel habits, pain, tenesmus and rectal bleeding, anorexia and weight loss. The natural history of this malignancy is not clearly defined due to the rarity of the disease. From data presented in Table 1, SCC of the rectum has a slight female predominance and the mean age at the time of diagnosis is 54.2 years in women and 59.4 years in men. Prognosis is worse than that of adenocarcinoma and there are some features that probably predict a poor outcome: nodal involvement, small cell or undifferentiated histological

characteristics, ulcerated or annular carcinomas, grade 3 or 4 and stage IV disease [18-20].

Immunochemistry is helpful in diagnosing SCC using several markers (cytokeratins AE1/AE3, 34BE12, CK5, involucrin, etc) in order to differentiate it from other small cell undifferentiated tumors [20].

The definite therapy is surgical resection of the affected rectum, either by low anterior resection (LAR) or by abdominoperineal resection (APR), depending on the location of the tumor and the patient's preference. An informed consent and a detailed discussion of complications, adjuvant therapy, recurrence and survival-death statistics are definite prerequisites before any operation. Copur *et al.* [17] propose the use of the squamous cell carcinoma antigen (SCC Ag) as a tumor marker for following up patients. In his study the SCC Ag was elevated at the time of recurrence and showed a partial response to com-

ination chemotherapy, with a decrease in the serum level.

The role of neoadjuvant radiotherapy (local control of the disease and downstaging) or adjuvant chemo and/or radiotherapy remains to be elucidated together with understanding the natural history of the disease. It seems that adjuvant therapy can be used in patients with nodal involvement, poorly differentiated cancers and metastatic disease without any proven effectiveness in outcome. Juturi *et al* [27] report that adjuvant combined chemotherapy reduced the size of liver metastasis in a patient with a SCC of the descending colon. However, large randomized prospective trials are needed to measure efficacy and benefits on survival and prognosis of complementary therapies.

Conclusion

SCC of the rectum is a rare and aggressive malignancy with a similar clinical presentation pattern, but a worse prognosis than that of adenocarcinoma, especially if positive nodes are involved or poor histological features are reported. Surgical resection is the treatment of choice, although radiation and chemotherapy can be useful in treating node-positive patients and advanced disease. It is possible and remains to be studied that aggressive combined chemo-radiotherapy is required pre- and postoperatively in order to control this aggressive malignancy.

Competing interests

The author(s) declare that they have no competing interests.

Authors' contributions

TT, LS and ND carried out the surgical procedures and contributed to the design of the study; TT and AM gathered the data, drafted the manuscript and critically revised it; EC performed the histological analysis of all surgical specimens and provided histological sections as figures for the manuscript; JV and VS revised and finally approved the manuscript for been published.

All authors read and approved the manuscript.

Acknowledgements

An informed consent of the patient for this publication has been signed.

References

- Raiford TS: **Epitheliomata of the lower rectum and anus.** *Surg Gynecol Obstet* 1933, **57**:21-35.
- Catell RB, Williams AG: **Epidermoid carcinoma of the anus and rectum.** *Arch Surg* 1943, **46**:336-349.
- Wiener MF, Polayes SH, Yidi R: **Squamous carcinoma with schistosomiasis of the colon.** *Am J Gastroent* 1962, **37**:48-54.
- Comer TP, Beahrs OH, Dockerty MB: **Primary squamous cell carcinoma and adenoacanthoma of the colon.** *Cancer* 1971, **58**:1111-1117.
- Williams GT, Blackshaw AJ, Morson BC: **Squamous carcinoma of the colon and its genesis.** *J Pathol* 1979, **129**:139-147.
- Lasser P, Elias D, Eschwege F: **A propos de 3 cas d'epitheliomas epidermoides du rectum.** *J Chir* 1980, **117**:377-380.
- Vezeridis MP, Herrera LO, Lopez GE, Ledesma EJ, Mittleman A: **Squamous-cell carcinoma of the colon and rectum.** *Dis Colon Rectum* 1983, **26**:188-191.
- Mel'nikov RA, Goshchitskii LG, Kovalek VK: **[Clinical manifestations of squamous cell carcinoma of the rectum] [Article in Russian].** *Vopr Onkol* 1984, **30**:76-83.
- Lafreniere R, Ketcham AS: **Primary squamous cell carcinoma of the rectum: report of a case and review of the literature.** *Dis Colon Rectum* 1985, **28**:967-972.
- Piggott JP, Williams GB: **Primary squamous cell carcinoma of the colorectum: case report and literature review of a rare entity.** *J Surg Oncol* 1987, **35**:117-119.
- Woods WG: **Squamous cell carcinoma of the rectum arising in an area of squamous metaplasia.** *Eur J Surg Oncol* 1987, **13**:455-458.
- Singh R, Wong DL: **Primary squamous cell carcinoma of the rectum (a case report and review of the literature).** *Indian J Pathol Microbiol* 1987, **30**:45-50.
- Prener A, Nielsen K: **Primary squamous cell carcinoma of the rectum in Denmark.** *APMIS* 1988, **96**:839-844.
- Schneider TA, Birkett DH, Vernava AM: **Primary adenosquamous and squamous cell carcinoma of the colon and rectum.** *Int J Colorectal Dis* 1992, **7**:144-147.
- Petrelli NJ, Valle AA, Weber TK, Rodriguez-Bigas M: **Adenosquamous adenocarcinoma of the colon and rectum.** *Dis Colon Rectum* 1996, **39**:1265-1268.
- Martinez-Gonzalez , Takahashi T, Leon-Rodriguez E, Gamboa-Dominguez A, Lome C, Garcia-Blanco MC, Bezaury P, Moran MA: **Case report of primary squamous carcinoma of the rectum.** *Rev Invest Clin* 1996, **48**:453-456.
- Copur S, Ledakis P, Novinski D, Mleczo KL, Frankforter S, Bolton M, Fruehling RM, VanWie E, Norvell M, Muhvic J: **Squamous cell carcinoma of the colon with an elevated serum squamous cell carcinoma antigen responding to combination chemotherapy.** *Clin Colorectal Cancer* 2001, **1**:55-58.
- Frizelle FA, Hobday KS, Batts KP, Nelson H: **Adenosquamous and squamous carcinoma of the colon and upper rectum.** *Dis Colon Rectum* 2001, **4**:341-346.
- Gelas T, Peyrat P, Francois Y, Gerard JP, Baulieux J, Gilly FN, Vignal J, Glehen O: **Primary squamous-cell carcinoma of the rectum. Report of six cases and review of the literature.** *Dis Colon Rectum* 2002, **45**:1535-1540.
- Anagnostopoulos G, Sakorafas GH, Kostopoulos P, Grigoriadis K, Pavlakis G, Margantinis G, Vugiouklakis D, Arvanitidis D: **Squamous cell carcinoma of the rectum: a case report and review of the literature.** *Eur J Cancer Care* 2005, **14**:70-74.
- Crissman JD: **Adenosquamous and squamous cell carcinoma of the colon.** *Am J Surg Pathol* 1978, **2**:47-54.
- Ouban AR, Nawab RA: **Diagnostic and pathogenetic implications of colorectal carcinomas with multidirectional differentiation: a report of 4 cases.** *Clin Colorectal Cancer* 2002, **1**:243-248.
- Michelassi F, Mishlove LA, Stipa F, Block GE: **Squamous-cell carcinoma of the colon. Experience at the University of Chicago, review of the literature, report of two cases.** *Dis Colon Rectum* 1998, **31**:228-235.
- Michelassi F, Montag AG, Block GE: **Adenosquamous-cell carcinoma in ulcerative colitis: report of a case.** *Dis Colon Rectum* 1988, **3**:323-326.
- Yurkadul G, De Reijke TM: **Rectal squamous cell carcinoma 11 years after brachytherapy for carcinoma of the prostate.** *J Urology* 2003, **169**:280-282.
- Audeay A, Han HW: **Does human papilloma virus have a role in squamous cell carcinoma of the colon and upper rectum?** *Eur J Surg Oncol* 2002, **28**:657-660.
- Juturi JV, Francis B, Koontz P, Wilkes J: **Squamous-cell carcinoma of the colon responsive to combination chemotherapy: review of two cases and review of the literature.** *Dis Colon Rectum* 1999, **42**:102-109.