

Case Report

Open Access

Tuberculosis and metastatic carcinoma coexistence in axillary lymph node: A case report

Manoj Pandey*¹, Elizabeth K Abraham², Chandramohan K¹ and Balakrishnan Rajan³

Address: ¹Department of Surgical Oncology, Regional Cancer Centre, Thiruvananthapuram, Kerala, India, ²Department of Pathology, Regional Cancer Centre, Thiruvananthapuram, Kerala, India and ³Department of Radiation Oncology, Regional Cancer Centre, Thiruvananthapuram, Kerala, India

Email: Manoj Pandey* - manojpandey@rcctvm.org; Elizabeth K Abraham - cytology@rcctvm.org; Chandramohan K - cm@vsnl.com; Balakrishnan Rajan - rajanrcc@techpark.net

* Corresponding author

Published: 7 April 2003

Received: 12 January 2003

World Journal of Surgical Oncology 2003, 1:3

Accepted: 7 April 2003

This article is available from: <http://www.wjso.com/content/1/1/3>

© 2003 Pandey et al; licensee BioMed Central Ltd. This is an Open Access article: verbatim copying and redistribution of this article are permitted in all media for any purpose, provided this notice is preserved along with the article's original URL.

Abstract

Background: Coexistence of cancer and tuberculosis in axillary lymph nodes is rare. Only seven cases have been reported in the literature.

Case Report: We report here a case of infiltrating ductal carcinoma breast metastasizing to the axillary lymph node along with tubercular granuloma in the same lymph node without primary mammary or pulmonary tuberculosis.

Conclusion: Primary tuberculosis coexisting with carcinoma is of rare occurrence. A possibility should always be borne in mind especially in patients from endemic areas.

Background

The synchronous occurrence of tuberculosis and carcinoma is unusual and association of the two has baffled surgeons and physicians for over two centuries. Coexistence of tuberculosis and metastatic carcinoma in axillary lymph nodes, without pulmonary or mammary tuberculosis is even rare. Warthin (1899) first described the coexistence of tuberculosis and cancer in axillary node [1], five other cases have been reported between 1902 and 1992 [2-4].

Case Presentation

A 52-year-old postmenopausal lady presented to the out patient clinic at Regional Cancer Centre, Trivandrum with a breast lump of 8 months duration. Examination re-

vealed a 3 × 2.5-cm well-defined hard mass in the upper inner quadrant of left breast. There were no palpable nodes in the left axilla. Contralateral breast and axilla were normal. There were no supraclavicular nodes. Biochemical parameters and chest roentgenogram were normal and metastatic work-up was negative.

Fine needle aspiration cytology revealed malignant cells. A modified radical mastectomy was carried out. Histopathology of the resected specimen revealed grade III infiltrating ductal carcinoma. Two of the axillary lymph nodes revealed metastatic carcinoma and granulomatous foci (figure 1) with Langhan's giant cells (figure 2), no acid-fast bacilli (AFB) could be demonstrated in the granuloma. The tumor was negative for estrogen and

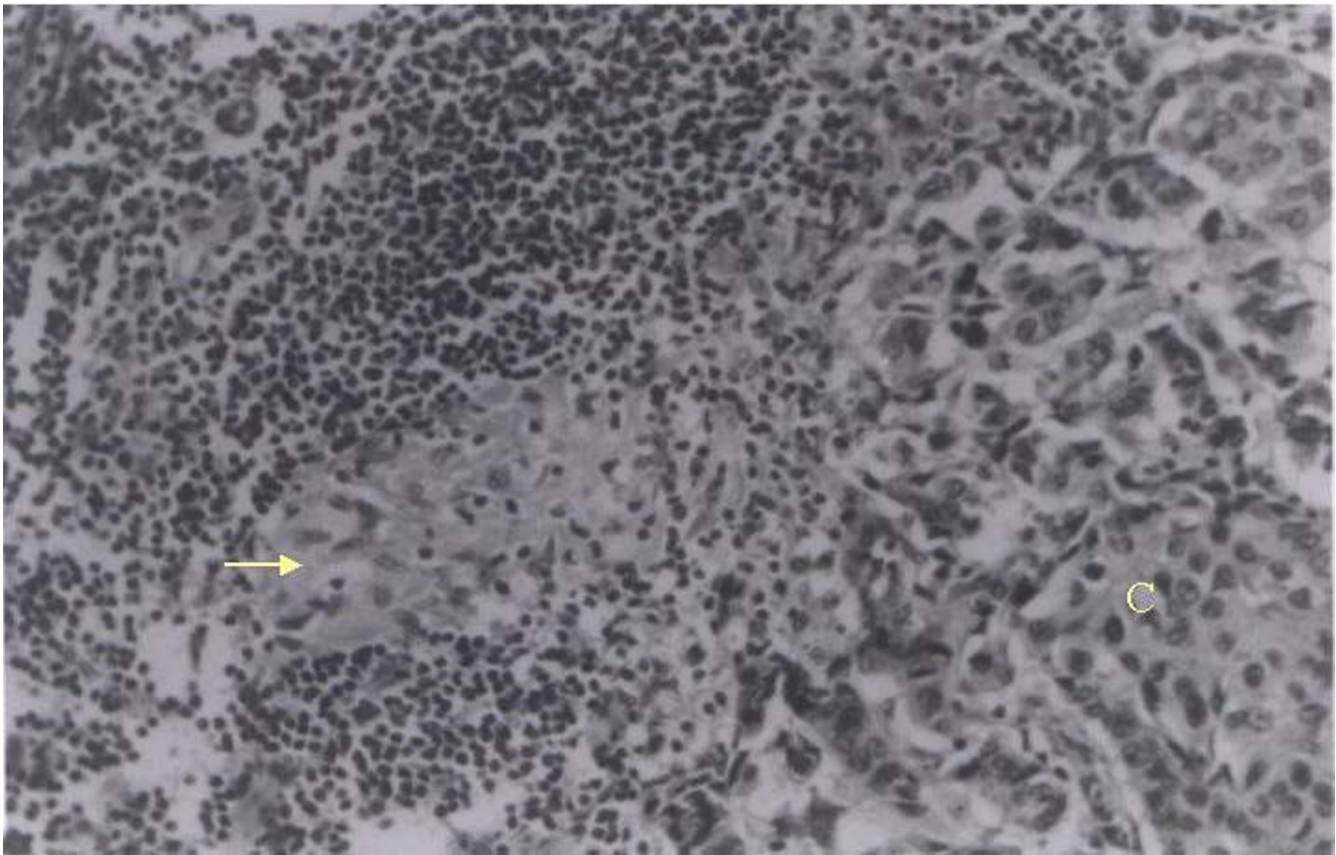


Figure 1

Section of lymph node showing metastatic adenocarcinoma (C) (towards the right) and granulomatous focus composed of epithelioid cells (arrow near center) (H and E \times 250)

progesterone receptors. Post operatively patient received short course, four drug anti tubercular treatment and six cycles of adjuvant chemotherapy with cyclophosphamide, methotrexate and 5-fluorouracil (CMF) followed by adjuvant radiotherapy to the chest wall and supraclavicular fossa. Patient is disease free after eight months of follow-up.

Discussion

The association of tuberculosis and cancer has been recorded in most of the organs and has been described and explained by many authors in many diverse ways. Kaplan et al. (1974) reviewed 58,245 patients with cancer and identified 201 cases of coexisting tuberculosis [5]. Highest prevalence was seen in patients with Hodgkin's disease (96/10,000 cases) followed by lung cancer (92/10,000), lymphosarcoma (88/10,000) and reticulum cell sarcoma (78/10,000) [5]. Among 14,742 cases of breast reviewed by them, only 28 had coexisting tuberculosis in breast, a

prevalence of 19/10,000. No case of axillary nodal coexistence was identified in their series [5].

Bayle first described the association of tuberculosis and carcinoma in 1810. He described "cavitation cancreuse" as one of the six types of tuberculosis, which appears to be the first published description of coexistence of the two [6]. The coexistence of breast cancer and tuberculosis has been described in over 100 cases [7,8], however its coexistence in the axillary node is rare. Only seven cases have been reported in the literature so far [2-4]. Majority of these cases reported breast cancer with axillary node showing tubercular foci, while our patient had a metastatic carcinoma and tubercular granulomatous foci in the same lymph node in the same high power field (figure 1) with the absence of tubercular foci elsewhere. The case is being reported for its rarity.

References

1. Warthin AS The coexistence of tuberculosis and carcinoma of the mammary gland *Am J Med Sci* 1899, **118**:25

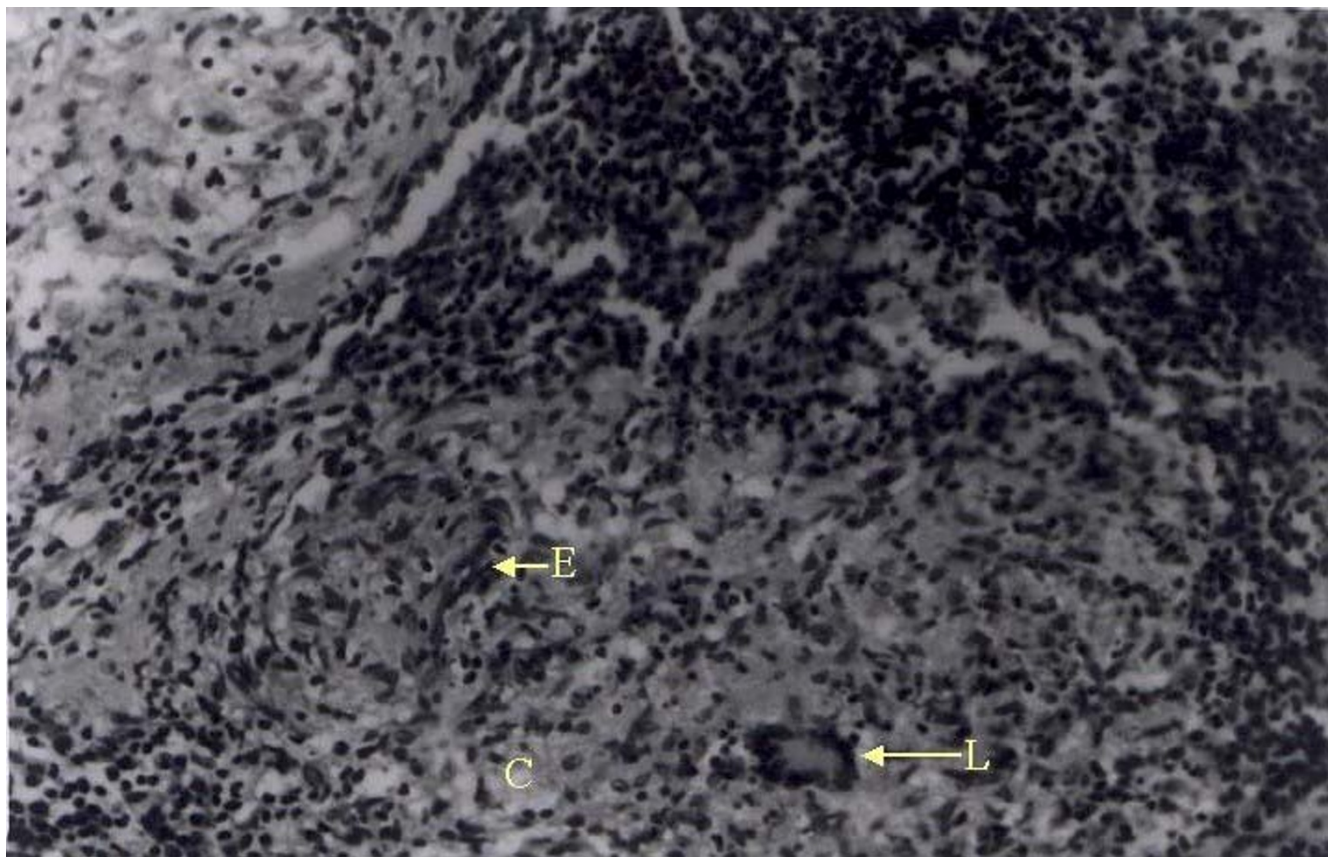


Figure 2

Section of lymph node showing tubercular granulomatous reaction composed of epithelioid cells (E) and Langhan's type of giant cells (L) with caseation (C) (H and E \times 250)

2. Miller RE, Solomen PF and West JP **The coexistence of carcinoma and tuberculosis of the breast and axillary lymph nodes** *Am J Surg* 1971, **121**:338-340
3. Grege A and Kienle J **Association of tuberculosis with carcinoma breast** *Radiol* 1969, **93**:1107-1108
4. Das DK, Mohil RS, Kashyap V, Khan IV, Mandal AK and Gulati SM **Colloid carcinoma of the breast with concomitant metastasis and a tubercular lesion in the axillary lymph nodes: a case report** *Acta Cytol* 1992, **36**:399-403
5. Kaplan MH, Armstrong D and Rosen P **Tuberculosis complicating neoplastic disease: a review of 201 cases** *Cancer* 1974, **33**:850-858
6. Bayle GI **Recherches sur la phthisie pulmonaire** *Gabon Paris* 1810,
7. Brammo-Cook F, O'Brian DS and Daly PA **Unusual breast masses. The sequential development of mammary tuberculosis and Hodgkin's disease in a young woman** *Cancer* 1988, **61**:1457-1459
8. Cheng W, Alagaratnam TT, Leung CY and Chen ACL **Tuberculosis and lymphoma of the breast in a patient with dermatomyositis** *Aust NZ J Surg* 1993, **63**:660-661

Publish with **BioMed Central** and every scientist can read your work free of charge

"BioMed Central will be the most significant development for disseminating the results of biomedical research in our lifetime."

Sir Paul Nurse, Cancer Research UK

Your research papers will be:

- available free of charge to the entire biomedical community
- peer reviewed and published immediately upon acceptance
- cited in PubMed and archived on PubMed Central
- yours — you keep the copyright

Submit your manuscript here:
http://www.biomedcentral.com/info/publishing_adv.asp

