

Case report

Open Access

Spontaneous Enterocutaneous Fistula 27-years Following Radiotherapy in a Patient of Carcinoma Penis

Chintamani*, Rohini Badran, Daniel Rk, Vinay Singhal and Dinesh Bhatnagar

Address: Department of Cancer and General Surgery, Vardhman Mahavir Medical College, Safdarjang Hospital, New Delhi, 110023, India

Email: Chintamani* - chintamani7@rediffmail.com; Rohini Badran - rohinibph@yahoo.com; Daniel Rk - dannyrk@yahoo.com; Vinay Singhal - mrinal5@rediffmail.com; Dinesh Bhatnagar - chintamani@doctor.com

* Corresponding author

Published: 03 November 2003

Received: 31 July 2003

World Journal of Surgical Oncology 2003, 1:23

Accepted: 03 November 2003

This article is available from: <http://www.wjso.com/content/1/1/23>

© 2003 Chintamani et al; licensee BioMed Central Ltd. This is an Open Access article: verbatim copying and redistribution of this article are permitted in all media for any purpose, provided this notice is preserved along with the article's original URL.

Abstract

Background: Radiotherapy in the radical doses can produce severe and often irreversible damage to the gut in the form of fibrosis, necrosis and fistulae formation. A previous pelvic surgery makes the gut extra-vulnerable. This is on account of adhesions to the pelvic wall, unless special care is taken during surgery to keep it out of the harms way, during adjuvant radiotherapy. These effects range from acute, to sub acute and delayed chronic manifestations like in the reported case.

Case report: A spontaneous low out put enterocutaneous fistula in a 68-year-old man following surgery and adjuvant radiotherapy given 27 years back for carcinoma penis is reported. Patient is making a satisfactory progress after three years of follow-up.

Conclusion: High dose external beam radiotherapy is known to produce deleterious side effects ranging from mild radiation enteritis to the development of internal and external fistulae. The effects may be acute, subacute or chronic. Presentation as spontaneous enterocutaneous fistula 27 years after radiotherapy is rare.

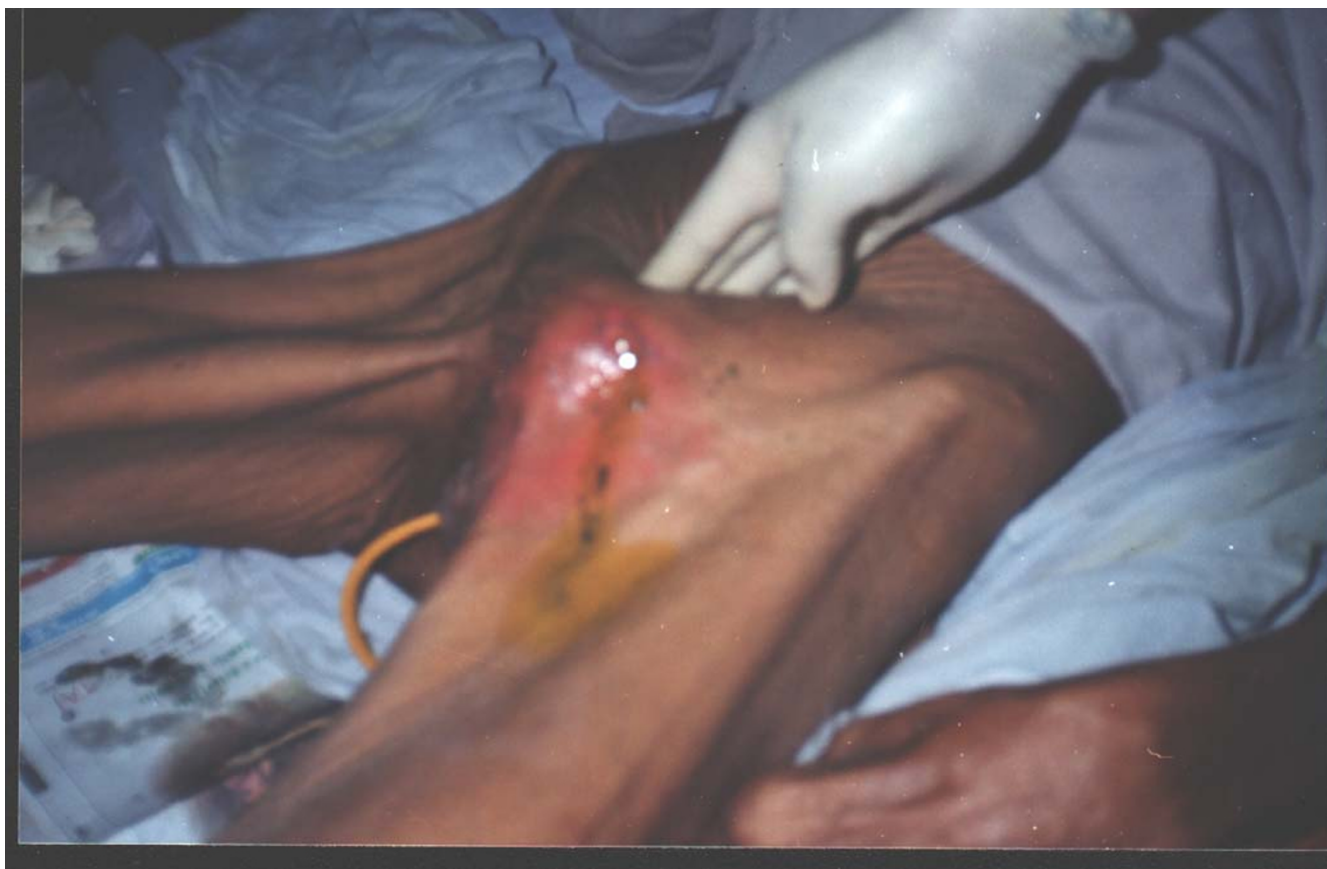Introduction

The damage caused by external beam radiation to the gut particularly in the dosages required for tumor regression i.e. ranging from 40–60 Gy is often severe and irreversible. This may manifest in the form of fibrosis, necrosis and fistulae formation in the bowel [1,2]. It is worse in immunocompromised patients like diabetics, patients receiving chemotherapy and following radiotherapy. Previous pelvic surgery like for carcinoma ovary, cervix and rectum etc. makes the gut extra vulnerable because of formation of adhesions to the pelvis [1–4]. Presentation of radiation-induced damage to the gut may be acute, subacute or

chronic and sometimes unusually delayed [3,4]. The maximum time lapse before development of enterocutaneous fistula following radiotherapy reported in the world literature is 15 years [5,6]. Presentation 27 years after receiving radiotherapy is rare.

Case report

A 65-year-old normally built gentleman presented to the outpatient with sudden onset discharge of faecal contents from an opening in the left inguinal region. The oral intake was adequate and he was passing stools and urine normally. There was no history suggestive of diabetes

**Figure 1**

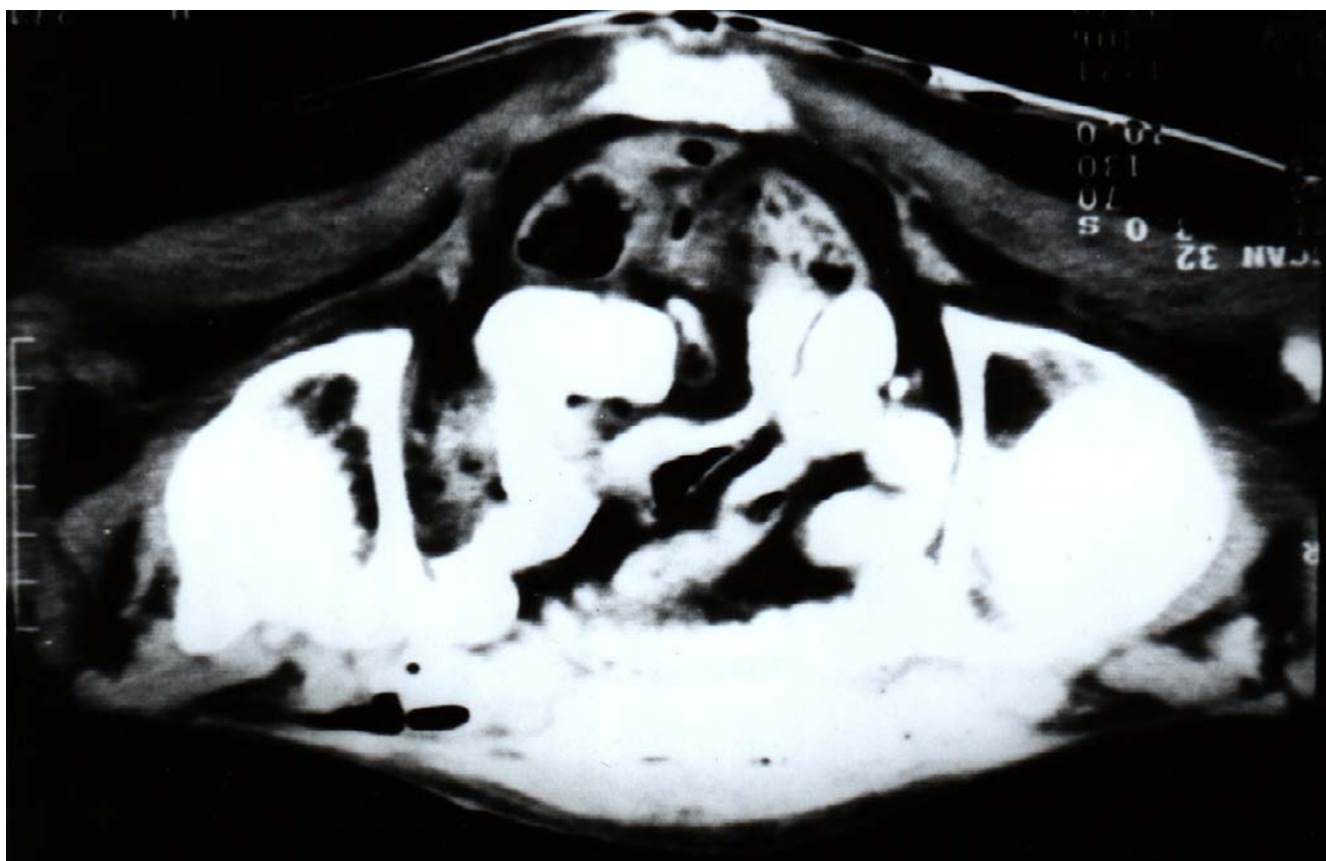
Fistulous opening in the left inguinal region (ileal contents can be seen coming out of the fistulous opening).

mellitus, tuberculosis or Crohn's disease. It started as a red, painful swelling in the inguinal region three days back, which ruptured spontaneously discharging faecal contents. Patient had undergone total penectomy with bilateral orchiectomy and perineal urethrostomy, 27 years earlier for carcinoma of the penis, followed by 60 Gy adjuvant external beam radiotherapy (EBRT) to the pelvis and para aortic nodes in 30 fractions. He was on a regular follow-up except for the last five years when he was lost to follow-up.

Examination revealed a well preserved; 140 lbs man (height 165 cm) with no features of anemia, hypoproteinemia, dehydration or electrolyte disturbances. His performance status was good and nutrition risk index (NRI) was >90 ($NRI = 1.519 \times \text{Serum albumin (g/l)} + 0.417 \times (\text{current wt/usual wt}) \times 100$). Based on subjective global assessment (SGA) (including clinical criteria like weight loss in previous six months, recent dietary intake compared to the usual intake, presence of anorexia etc.) and Eastern Cooperative Oncology Group (ECOG) crite-

ria his performance and nutritional status was good. Abdomen was scaphoid with no organomegaly or any lymphadenopathy.

There was a discharging fistulous opening in the left ilio-inguinal area approximately 5 cm from the pubic symphysis (figure 1). The discharge was faecal with no evidence of pus in it. The routine investigations including the blood biochemistry were normal. Abdominal ultrasound was normal. Contrast enhanced computed tomography (CECT) abdomen (figure 2) revealed an enterocutaneous fistula and there was no evidence of any recurrent or remnant disease. Fistulogram (figure 3) confirmed the communication with the small bowel. Since the patient was well preserved, with good performance and nutritional status, with adequate oral intake, features of intestinal obstruction, evidence of any underlying malignancy and it being a low output fistula (with a daily out put less than 100 ml), he was managed conservatively on expectant treatment.

**Figure 2**

Contrast enhanced computed scan showing the enterocutaneous fistula and no evidence of any remnant or recurrent disease.

The general management included replenishment of fluid and electrolyte losses, and nutritional supplements. The local skin care involved using skin protective emollients creams (containing dimethicone 20%, zinc oxide 7.5%, calamine 1.5% and cetrimide 1.125%) and egg white around the fistula site to protect the skin. An ileostomy bag was fitted in order to allow the fistula to close spontaneously and to measure the output in 24 hours accurately. The daily intake and output chart was maintained to accurately assess the loss for replacement. He made a satisfactory recovery with the output gradually reducing to less than 5 ml and was discharged on the tenth day. Patient has made a satisfactory recovery and now has completed three years on follow-up.

Discussion

The damage caused to the gut by external beam radiotherapy to the pelvis when used in tumoricidal doses (40–60 Gy) is severe and often irreversible. The damage observed is more severe in patients receiving radiotherapy after prior pelvic surgery like in advanced cancer of the cervix

where a combination of radiation therapy and pre-treatment surgical staging is done in women with advanced disease [1,2]. The major underlying cause of these spontaneous enterocutaneous fistulae is pelvic malignancies, in particular, cancer of the cervix where the formation of spontaneous enterocutaneous fistulae following radiotherapy is highest [3–6]. There is a very strong correlation between pre-treatment surgical staging and radiation dose [3,5–8]. Fractionated doses of 30–40 Gy can cause damage to the gut. Severe damage may follow dosages more than 60 Gy. In day-to-day routine practice one refers to the tolerance doses documented by Rubin and Cassarett [5] as TD 5/5 which indicates the probability of 5% complication rates within five years and TD 50/5 indicating the probability of 50% complication rates within five years.

In an effort to achieve an uncomplicated loco-regional tumor control it is important to minimize the radiation to normal structures while maximizing the dose to the tumor. The development of computers and modern imag-

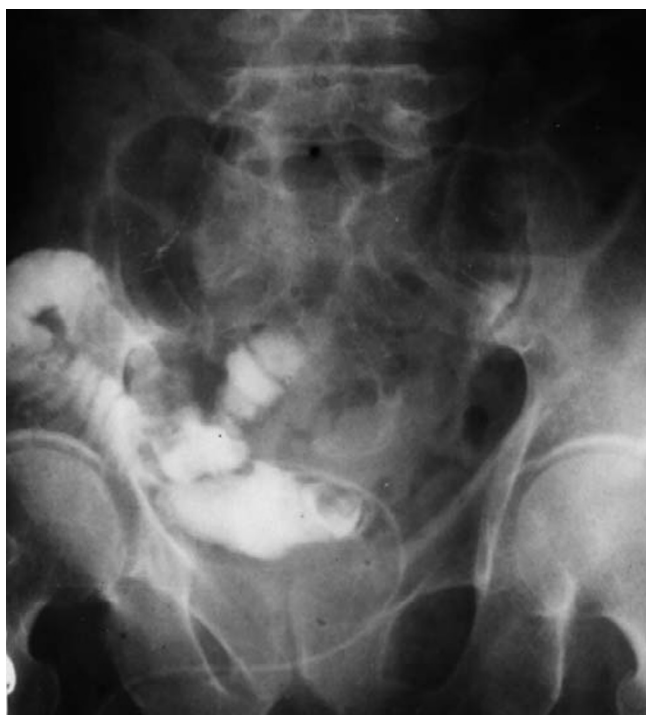

Figure 3
Fistulogram showing the communication with the small bowel.

ing techniques has led to the evolution of a "three dimensional treatment planning and dose delivery" system, which may eventually assist radiation oncologist in achieving this goal [5].

In addition to the potential for an increased morbidity and mortality, the development of fistula in a cancer patient can prohibit any definitive or surgical treatment for the underlying malignancy and attempts at closure of the fistula [6–9]. Further more immunocompromised states or nutritional deficiencies in these patients may reduce the likelihood of fistula resolution. Development of an enterocutaneous fistula in a patient with active disease may also limit the ability of patient to proceed with adjuvant curative or palliative treatment [6]. Fistula occurring after 30 days of the primary therapy i.e. either surgery or radiotherapy is defined as spontaneous enterocutaneous fistula [8].

Enterocutaneous fistulae are classified into four types based on the modified Sitzes-Serra classification [8] proposed by Shein and Decker [6–8]. Type 1 fistula are esophageal, gastric, and duodenal fistulae, type II fistula Involve small bowel; type III fistula Involve large bowel

and type IV fistula where all the afore mentioned drains through a large abdominal wall defect.

Based on the output, the fistulas are classified as high and low output fistula. Fistulae producing less than 500 cc output per day are classified as low output fistulae while those with >500 ml/ day are classified as high output fistulae and this has a bearing on the management [8]. High out put fistulas usually require surgical intervention while low output fistulae in well-preserved individuals may be managed conservatively [6–8].

The presentation may be in the form of fibrosis, necrosis and fistulae of the bowel. Pelvic surgery for carcinoma cervix, rectum or ovary makes the gut extra vulnerable due to adhesions to the pelvic walls unless special care is taken during surgery to keep the small bowel out of the harms way [1,2]. Various parts of the gut in the order of increasing tolerance to radiations are jejunum, ileum, transverse colon and rectum [2,6–8]. The time interval between irradiation and the clinical manifestation of bowel injury cannot be predicted and is divided in to four distinct phases of radiation effects [1,7,9]. Acute Phase, where mainly the mucosa is affected in the form of acute radiation mucositis, sub acute phase occurring over a period of one to two years, affecting predominantly the submucosa and a chronic phase affecting all layers of the bowel. The chronic phase usually occurs within three to four years following irradiation.

Late chronic effects are in the form of progressive obliterative endarteritis and ischemia. The resultant damage ranges from chemical cellulitis, ulceration, fibrosis and necrosis of the bowel wall to fistulae formation. The reported case falls in to this category.

Management of fistulas is divided into three phases: *Phase I* involves the correction of fluid and electrolyte imbalances. The fistula drainage is accurately measured and replaced milliliter by milliliter with normal saline. Meticulous skin care is provided around the fistula using skin protective creams. Ileostomy bag is placed on the opening to allow for evaluation of spontaneous closure and monitoring the daily output. The associated intra-abdominal abscesses are drained and appropriate antibiotics started.

Phase II consists of accurate diagnosis of the origin of fistula and begins simultaneously with phase I. The diagnosis of the fistula can be accomplished by using water-soluble iodinated media through a small catheter inserted in to the fistulous opening (fistulogram). Because of the rapid absorption of the water-soluble material, x-ray should be taken immediately. Combination with barium studies can accurately establish the site of the fistula in case of difficulty. CECT can delineate the fistula and also

locate any recurrent or remnant tumor. Hyperalimentation is initiated and observation regarding the possibility of spontaneous closure of the fistula is done during this phase. The fistula closes spontaneously if there is no distal obstruction, no underlying malignancy, and no foreign body in the intestinal wall, if the fistula tract is not lined by fibrous tissue, if the fistulous opening is not very large (<1 cm) and if there is no eversion of mucous membrane and epithelialization of the fistulous tract. All these conditions in addition to high output are an indication for surgery, which is a part of phase III [6-9].

The phase III consists of surgical correction and the principles are well established barring a few controversies regarding the type and extent of the surgical procedure to be undertaken. Bypass surgery is not recommended as the damage may be difficult to predict correctly and therefore it has a high failure rate, high mortality and causes blind loop syndrome. Furthermore leaving behind the diseased bowel may act as a possible source of further complications. Therefore resection of the matted diseased bowel with anastomosis of healthy segments is considered a better option. In critically ill patients, exteriorization of both ends (as ostomy and mucus fistula) is considered worthwhile, in order to have the patient for definitive repair when he is clinically stable. This is also applied to rectal irradiation injuries where Hartman's procedure may be contemplated [8-11].

The extent of damage in a radiation-injured bowel is difficult to predict and the injury usually may be more severe than anticipated, the successful management of these cases therefore requires an early diagnosis and carefully staged planning for treatment [2,3].

The maximum time lapse reported between exposure to radiotherapy and development of radiation induced enteropathy in the form of enterocutaneous fistula is 15 years [5,6]. The development of a spontaneous enterocutaneous fistula 27 years after radiotherapy is rare and to the best of our knowledge this is the first report of such a delayed presentation.

Acknowledgement

The written consent is obtained from the patient regarding permission to publish this case report in the World Journal of Surgical Oncology.

References

1. Marks G and Mohudden M: **surgical management of radiation-injured intestine.** *Surg Clin N Am* 1983, **63**:81-96.
2. Piver MS and Lele S: **Enterovaginal and enterocutaneous fistulae in women with gynecologic malignancies.** *Obstet Gynecol* 1976, **48**:560-563.
3. Piver MS, Vongtama V and Barlow JJ: **Paraaortic lymph node irradiation for carcinoma of the uterine cervix using split course technique.** *Gynecol Oncol* 1975, **3**:168-175.
4. Clarke-Pearson DL, Chin NO, DeLong ER, Rice R and Creasman WT: **Surgical management of intestinal obstruction in ovarian cancer. I Clinical features, postoperative complications and survival.** *Gynecol Oncol* 1987, **26**:11-18.
5. Emami B, Lyman J, Brown A, Coia L, Goitein M, Munzenrieder JE, Shank B, Solin L and Wesson M: **Tolerance of normal tissue to therapeutic irradiation.** *Int J Radiat Oncol Biol Phys* 1991, **21**:123-135.
6. Chamberlain RS, Kaufman HL and Danforth DN: **Enterocutaneous fistulae in cancer patients: etiology, management, outcome and impact on further treatment.** *Am Surg* 1998, **64**:1204-1211.
7. Schein M and Decker GAG: **Postoperative external alimentary tract fistulas.** *Am J Surg* 1991, **161**:435-438.
8. Sitges-Serra A, Jaurrieta E and Sitges-Creus A: **Management of postoperative enterocutaneous fistulas: The role of parenteral nutrition and surgery.** *Br J Surg* 1989, **69**:147-150.
9. Russell JC and Wetch JP: **Operative management of radiational injuries of intestinal tract.** *Am J Surg* 1979, **137**:433-442.
10. Gallard RB and Spencer JJ: **Radiation induced gastrointestinal fistulae.** *Ann R Coll Surg England* 1986, **68**:5-7.
11. Dencker H, Johnson JE, Liedberg G and Tibblin S: **Surgical aspects of radiation injury to small and large intestine.** *Acta Chir Scand* 1971, **137**:692-695.

Publish with **BioMed Central** and every scientist can read your work free of charge

"BioMed Central will be the most significant development for disseminating the results of biomedical research in our lifetime."

Sir Paul Nurse, Cancer Research UK

Your research papers will be:

- available free of charge to the entire biomedical community
- peer reviewed and published immediately upon acceptance
- cited in PubMed and archived on PubMed Central
- yours — you keep the copyright

Submit your manuscript here:
http://www.biomedcentral.com/info/publishing_adv.asp

