

CORRECTION

Open Access



Correction: Periosteal preservation: a new technique in resection of bone high-grade malignant tumors in children—about eleven cases

Mahmoud Smida^{1,2*}, Ameni Ammar^{1,2}, Faten Fedhila^{1,3}, Wiem Douira^{1,4} and Samia Sassi^{1,5}

Correction: World J Surg Onc 20, 312 (2022)
<https://doi.org/10.1186/s12957-022-02749-1>

Following publication of the original article [1], the author reported that the arrows, chevron and stars in Figs. 1 and 2 were removed during the corrections stage. These were added back to the images and the original article has been updated.

Published online: 24 May 2023

Reference

1. Smida M, Ammar A, Fedhila F, et al. Periosteal preservation: a new technique in resection of bone high-grade malignant tumors in children—about eleven cases. World J Surg Onc. 2022;20:312. <https://doi.org/10.1186/s12957-022-02749-1>.

The original article can be found online at <https://doi.org/10.1186/s12957-022-02749-1>.

*Correspondence:

Mahmoud Smida
mahmoud.smida@yahoo.fr

¹ Tunis Faculty of Medicine, Tunis El Manar University, Tunis, Tunisia

² Department of Trauma, Orthopedics Kassab Institute, 2010 Manouba, Tunisia

³ Oncology Unit, Tunis Children Hospital, Bab Saadoun, 1007 Tunis, Tunisia

⁴ Department of Radiology, Tunis Children Hospital, Bab Saadoun, 1007 Tunis, Tunisia

⁵ Department of Pathology, Salah Azaiez Institute, Bab Saadoun, 1007 Tunis, Tunisia



© The Author(s) 2023. **Open Access** This article is licensed under a Creative Commons Attribution 4.0 International License, which permits use, sharing, adaptation, distribution and reproduction in any medium or format, as long as you give appropriate credit to the original author(s) and the source, provide a link to the Creative Commons licence, and indicate if changes were made. The images or other third party material in this article are included in the article's Creative Commons licence, unless indicated otherwise in a credit line to the material. If material is not included in the article's Creative Commons licence and your intended use is not permitted by statutory regulation or exceeds the permitted use, you will need to obtain permission directly from the copyright holder. To view a copy of this licence, visit <http://creativecommons.org/licenses/by/4.0/>. The Creative Commons Public Domain Dedication waiver (<http://creativecommons.org/publicdomain/zero/1.0/>) applies to the data made available in this article, unless otherwise stated in a credit line to the data.

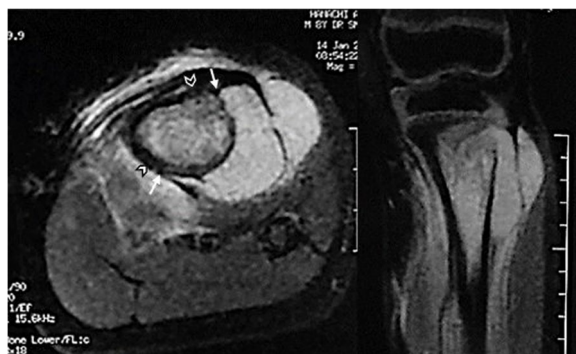


Fig. 1 Ewing sarcoma of the proximal tibia in an 8-year-old boy. MR images show an extra-compartmental involvement and a partially circumferential (medial) respect for the CPU. Footnotes: arrows: axial edges; chevrons: level of the periosteal section

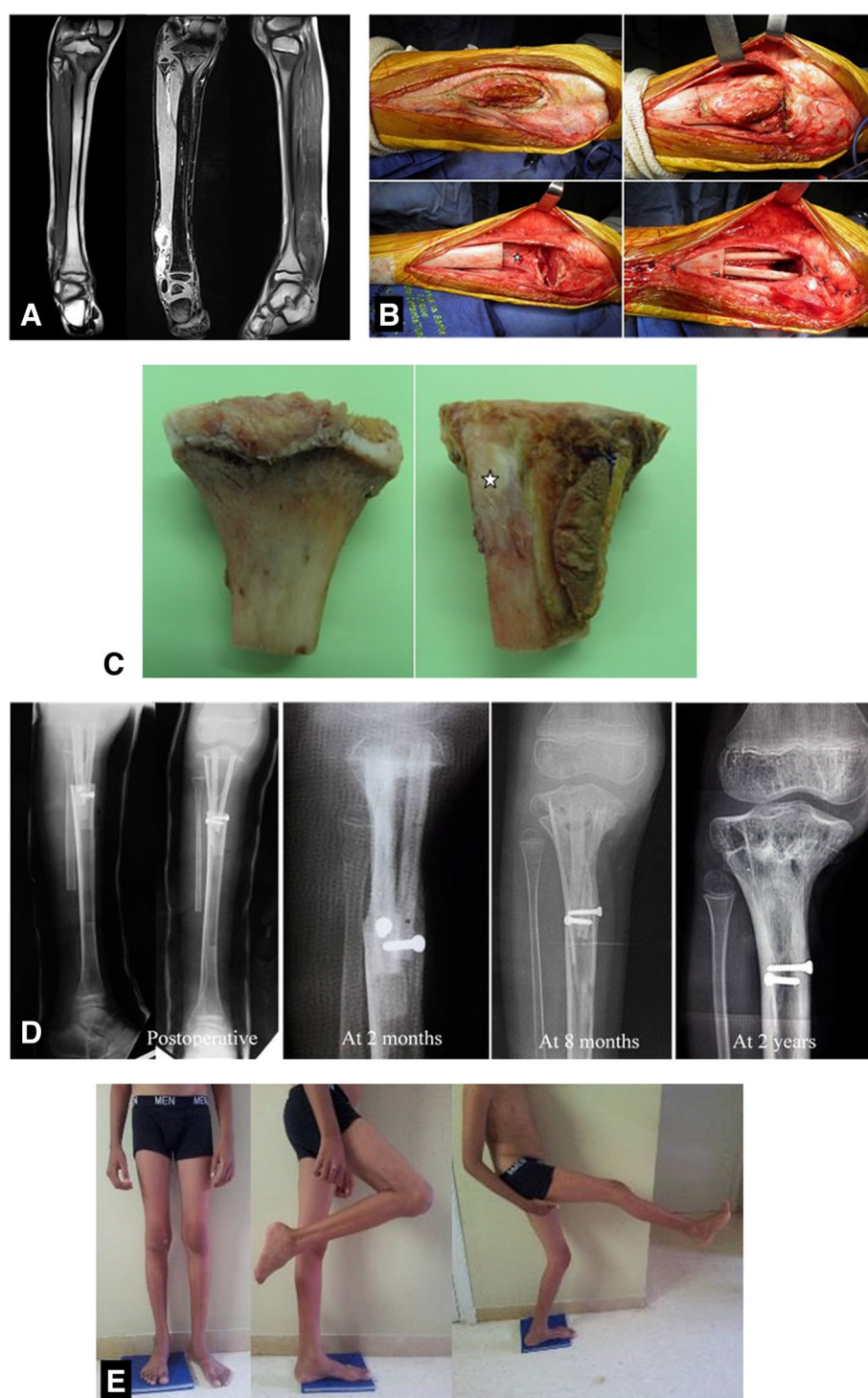


Fig. 2 **A** Ewing sarcoma of the distal right fibula with purely intraosseous second localization in the homolateral proximal tibia in a 9-year-old boy. **B** Subperiosteal resection of the tibial localization with the previous site of biopsy. Tripod reconstruction was performed with non-vascularized autografts (2 fibulas and one tibia cortical). The distal fibula tumor was removed (at the same surgical time) (footnote: star: periosteum preserved). **C** Gross specimen with posterior and medial aspects. Proximal tibia without its periosteum and only the previous site of biopsy was resected with the tumor (footnote: star: anterior tibial tuberosity). **D** Serial radiographs showing rapid bone consolidation and good reconstruction. **E** Good functional result at 3-year follow-up. Little lower limb discrepancy. MSST = 28/30