

Case report

Open Access

## Metastatic prostate cancer masquerading clinically and radiologically as a primary caecal carcinoma

Muhammad A Kabeer<sup>1</sup>, Edward Lloyd-Davies<sup>2</sup>, Giles Maskell<sup>3</sup>, Rolf Hohle<sup>1</sup> and Joseph Mathew\*<sup>1</sup>

Address: <sup>1</sup>Department of Histopathology, Royal Cornwall Hospital, Truro, TR1 3LJ, UK, <sup>2</sup>Department of Surgery Royal Cornwall Hospital, Truro, TR1 3LJ, UK and <sup>3</sup>Department of Clinical Imaging, Royal Cornwall Hospital, Truro, TR1 3LJ, UK

Email: Muhammad A Kabeer - muhammad.kabeer@rcht.cornwall.nhs.uk; Edward Lloyd-Davies - edward.Lloyd-Davies@rcht.cornwall.nhs.uk; Giles Maskell - giles.maskell@rcht.cornwall.nhs.uk; Rolf Hohle - rolf.hohle@rcht.cornwall.nhs.uk; Joseph Mathew\* - joe.mathew@rcht.cornwall.nhs.uk

\* Corresponding author

Published: 07 January 2007

Received: 11 August 2006

World Journal of Surgical Oncology 2007, 5:2 doi:10.1186/1477-7819-5-2

Accepted: 07 January 2007

This article is available from: <http://www.biomedcentral.com/1477-7819/5/2>

© 2007 Kabeer et al; licensee BioMed Central Ltd.

This is an Open Access article distributed under the terms of the Creative Commons Attribution License (<http://creativecommons.org/licenses/by/2.0>), which permits unrestricted use, distribution, and reproduction in any medium, provided the original work is properly cited.

### Abstract

**Background:** Prostatic carcinoma is the second most common cause of cancer-related deaths in males in the West. Approximately 20% of patients present with metastatic disease. We describe the case of a patient with metastatic prostate cancer to the bowel presenting clinically and radiologically as a primary caecal cancer.

**Case presentation:** A 72 year-old man presented with abdominal discomfort and a clinically palpable caecal mass and a firm nodule on his thigh, the latter behaving clinically and radiologically as a lipoma. Computed tomographic (CT) scan showed a luminally protuberant caecal mass with regional nodal involvement. The patient was being treated (Zoladex<sup>®</sup>) for prostatic cancer diagnosed 6 years previously and was known to have bony metastases. On admission his PSA was 245.4 nmol/ml. The patient underwent a right hemicolectomy. Histology showed a poorly differentiated adenocarcinoma which was PSA positive, confirming metastatic prostatic adenocarcinoma to the caecum. The patient underwent adjuvant chemotherapy and is free from recurrence a year later.

**Conclusion:** Metastasis of prostatic carcinoma to the bowel is a very rare occurrence and presents a challenging diagnosis. The diagnosis is supported by immunohistochemistry for PSA. The treatment for metastatic prostate cancer is mainly palliative.

### Background

Prostatic carcinoma is the second most common cause of cancer related deaths in males in the West [1]. Approximately 20% of patients present with metastatic disease but colo-rectal involvement is rare[2]. We describe the case of a patient with metastatic prostate cancer to the bowel presenting as primary caecal cancer.

### Case presentation

A 72-year-old man presented with abdominal discomfort with small amount of bleeding per rectum and a clinically palpable lump in the right iliac fossa. He also had a large, firm, mobile lump on his left thigh.

He had been treated six years previously for prostatic carcinoma which was Gleason's grade 3+3= 6. Bony metas-

tases had been diagnosed recently. He was on Zoladex® injections.

Clinical examination showed a 6 cm hard, mobile, non-tender mass in his right iliac fossa. Digital rectal examination was unremarkable. Rigid sigmoidoscopy revealed radiation proctitis, which would explain his bleeding per rectum. CT scan of abdomen showed a caecal tumour with regional lymphadenopathy and vertebral metastasis (Figure 1). A non-palpable left iliac mass was identified: this was defined as internal iliac nodes lymphadenopathy, associated with partial obstruction of the left ureter (the possibility of prostatic metastasis to these nodes was considered). A fatty mass lesion was identified in the left thigh, the CT appearances of which were that of a simple lipoma; this has remained unchanged on subsequent CT scans. Bone scan confirmed bony metastasis in the 12<sup>th</sup> thoracic and 1<sup>st</sup> lumbar vertebrae and rib cage. In 2003, there was a gradual rise in his PSA levels which had gone upto 233 nmol/ml. Zoladex® injections were then started and his PSA levels fell to 6.3 nmol/ml by January 2004. This however had gradually risen again to 254.4 nmol/ml on admission, inspite of being on Zoladex®.

The patient underwent a right hemicolectomy for what appeared to be an obvious locally advanced luminally protuberant caecal carcinoma with mesenteric lymph nodal involvement. Histopathological examination of the specimen showed a poorly differentiated adenocarcinoma of the caecum extending throughout the whole bowel wall and breaching the serosa with metastatic involvement of 5 of 15 paracolic lymph nodes (Figure 2). The possibility of prostatic metastasis was considered and confirmed on immunohistochemical staining for PSA (Figure 2) and, given this, stains for CK7, CK20 and CDX2 immunoprofile were considered unnecessary. The final histological diagnosis was of a metastatic prostatic adenocarcinoma to the caecum. The patient underwent adjuvant chemotherapy with Docetaxel and Paclitaxel and is free from recurrence a year later.

## Discussion

Progression of prostate cancer occurs either by direct extension or metastasis through haematogenous or lymphatic routes. The most commonly involved organs are the seminal vesicles, base of the bladder, bones (mainly axial skeleton) and lymph nodes[1]. Widespread visceral involvement is quite rare. Some unusual sites of spread have been described in literature as the parotid gland[3], oesophagus[4], vocal cords[5], larynx[6], lung & bronchus[7], stomach[8], liver[9], skin[10], umbilicus [11], sphenoid sinus[12], cranium[13], meninges[14], testes[15], penis[16], breast[17], mediastinum[18], thymus [19], orbit[20], uveal tract[21], brain[22], cerebellum[23] and bones[24]. Rectal seeding on needle biopsy[25] and

direct involvement occasionally occurs [26], but distant metastasis to the bowel is quite rare (prevalence 1–4% in autopsy series)[27]. So far only three accounts of metastasis to the distant bowel have been recorded, one involving the small bowel[27] and the other two involving the rectosigmoid[28,29].

It is important to distinguish primary from metastatic colorectal lesions, especially in the presence of a previous history of cancer at another site, in order to facilitate appropriate management. This is best achieved by defining the tumour type on histopathologic grounds and, in this instance, by immunohistochemical staining for PSA[17,30]. The treatment of primary colonic adenocarcinomas is potentially curative with a combination of surgery and chemo-irradiation; treatment of colonic metastasis depends on the primary site and might not be 'curative'. The treatment of metastatic disease from the prostate is purely palliative; hormonal treatment represents the standard[31], although this can be combined with debulking surgery to reduce the tumour load where feasible. However, the impact of debulking surgery on patient survival is not known. Metastatic prostate cancer has poor prognosis and survival rates range from 1 to 3 years[8].

The response of prostatic carcinoma to oestrogen therapy has been well established[32] but patients often become refractory after prolonged treatment. Options for hormone-refractory prostate cancer include secondary hormonal treatment (anti-androgens), radiotherapy and cytotoxic chemotherapy. The metastatic component, as described in our case, can be managed with debulking surgery and may well need adjuvant chemotherapy or secondary hormonal treatment to achieve reasonable regression of disease.

## Conclusion

Metastasis of prostatic carcinoma to the bowel is a very rare occurrence and presents a challenging diagnosis. The mainstay of diagnosis is histopathology supported by immunohistochemistry for PSA.

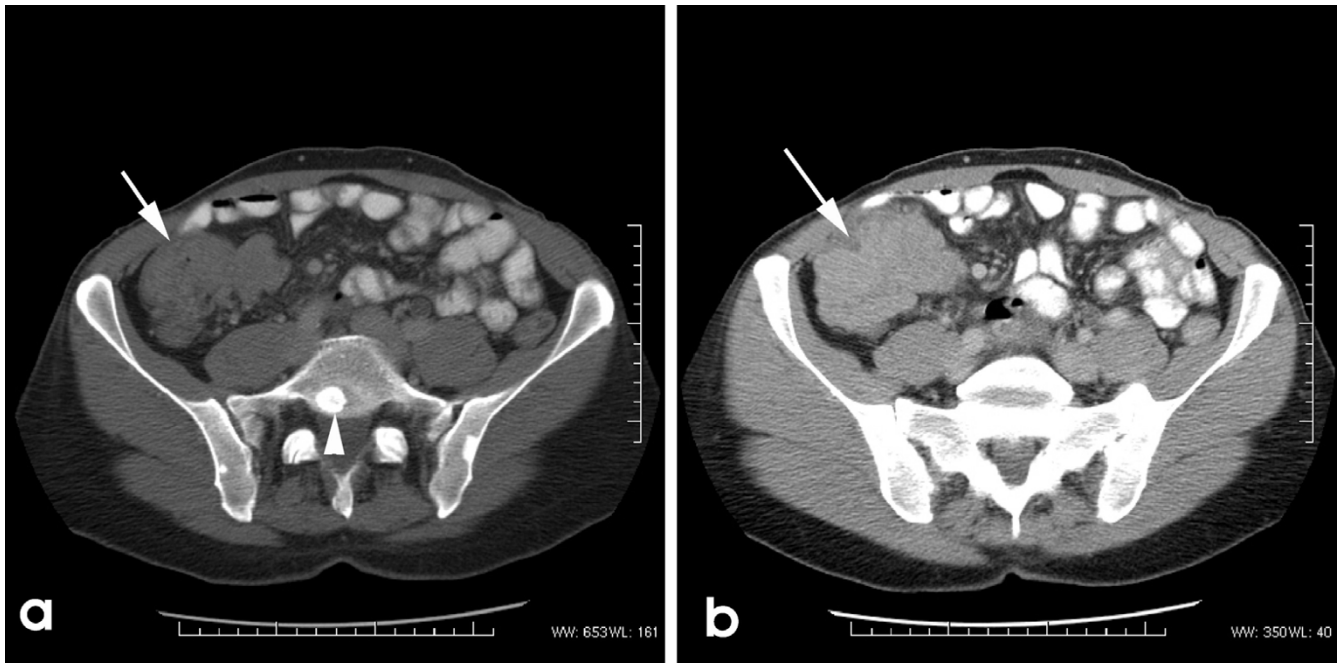
Palliative treatment remains the mainstay of therapy for metastatic prostate cancer and hormonal therapy represents the standard with debulking surgery where feasible.

## Competing interests

The author(s) declare that they have no competing interests.

## Authors' contributions

MAK – research, acquisition of data, acquisition of consent, writing, drafting and revision of manuscript



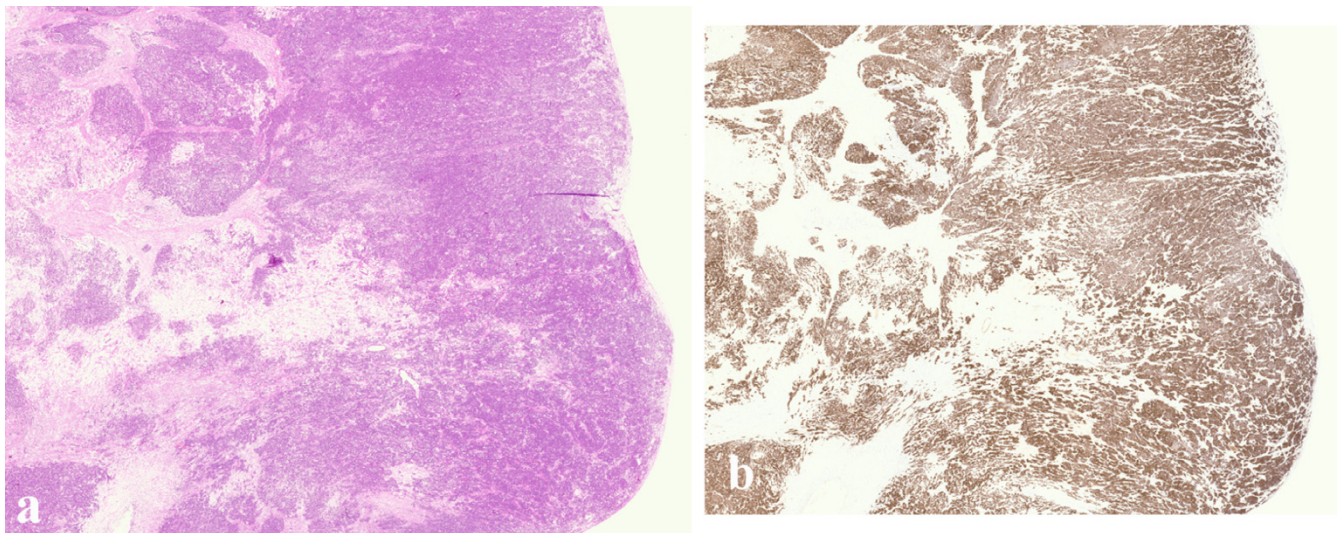
**Figure 1**

a) Imaging shows a well defined caecal tumour (arrow) with evidence of vertebral metastasis (arrowhead). b) The tumour is irregular in outline (arrow) and is closely approximated to the anterior abdominal wall.

ELD – lead colorectal surgeon involved in this patients management and critical review of manuscript

RH – reporting pathologist, involved in discussions leading to manuscript preparation, contribution of data and critical review of manuscript

GM – consultant in charge of imaging and diagnosis, contribution of images, critical review of manuscript



**Figure 2**

a) Histology shows a well defined intraluminal, protuberant tumour invading the submucosa. This invasive tumour extends to pericolonic fibroadipose tissue. b) This tumour is positive with PSA, confirming its metastatic origin from a primary prostatic carcinoma.

JM – lead colorectal pathologist, involved in diagnosis, contributed to manuscript conception, involved in collating material, organising manuscript, critical reviews of manuscript

All authors have read and approved the final manuscript

## Acknowledgements

Written consent was obtained from the patient for publication of this case report.

## References

- Epstein JI: *The Lower Urinary Tract and Male Genital System, Pathologic Basis Of Disease* 7th edition. London: Elsevier-Saunders; 2004.
- Siddiqui E, Mumtaz FH, Gelister J: **Understanding prostate cancer.** *J R Soc Health* 2004, **124**:219-221.
- Kirkali Z, Koyuncuoglu M, Pabuccuoglu U, Guneri A, Mungan U: **Prostatic carcinoma presenting with painless parotid mass.** *Urology* 1995, **46**:406-407.
- Nakamura T, Mohri H, Shimazaki M, Ito Y, Ohnishi T, Nishino Y, Fujihiro S, Shima H, Matsushita T, Yasuda M, Moriwaki H, Muto Y, Deguchi T: **Esophageal metastasis from prostate cancer: diagnostic use of reverse transcriptase-polymerase chain reaction for prostate-specific antigen.** *J Gastroenterol* 1997, **32**:236-240.
- Park YW, Park MH: **Vocal cord paralysis from prostatic carcinoma metastasizing to the larynx.** *Head Neck* 1993, **15**:455-458.
- Coakley JF, Ranson DL: **Metastasis to the larynx from a prostatic carcinoma. A case report.** *J Laryngol Otol* 1984, **98**:839-842.
- Hofland CA, Bagg MD: **An isolated pulmonary metastasis in prostate cancer.** *Mil Med* 2000, **165**:973-974.
- Christoph F, Grunbaum M, Wolkers F, Muller M, Miller K: **Prostate cancer metastatic to the stomach.** *Urology* 2004, **63**:778-779.
- Taylor J, Lindor K: **Metastatic prostate cancer simulating sclerosing cholangitis.** *J Clin Gastroenterol* 1993, **16**:143-145.
- Spiller JC, Hall JC, Watson KR: **Cancer of prostate metastatic to the skin diagnosed by immunoperoxidase staining.** *Mo Med* 1991, **88**:642-644.
- Fukuda H, Saito R: **A case of Sister Mary Joseph's nodule from prostatic cancer.** *J Dermatol* 2006, **33**:46-51.
- McClatchey KD, Lloyd RV, Schaldenbrand JD: **Metastatic carcinoma to the sphenoid sinus. Case report and review of the literature.** *Arch Otorhinolaryngol* 1985, **241**:219-224.
- Lippman SM, Buzaid AC, Iacono RP, Steinbronn DV, Stanicic TH, Rennels MA, Yang PJ, Garewal HS, Ahmann FR: **Cranial metastases from prostate cancer simulating meningioma: report of two cases and review of the literature.** *Neurosurgery* 1986, **19**:820-823.
- Scarrow AM, Rajendran PR, Marion D: **Metastatic prostate adenocarcinoma of the dura mater.** *Br J Neurosurg* 2000, **14**:473-474.
- Bashein HJ, Ginsberg P, Zond JR, Finkelstein LH: **Testicular metastasis from adenocarcinoma of the prostate.** *J Am Osteopath Assoc* 1991, **91**:895-897.
- Nakayama F, Sheth S, Caskey CI, Hamper UM: **Penile metastasis from prostate cancer: diagnosis with sonography.** *J Ultrasound Med* 1997, **16**:751-753.
- Sahoo S, Smith RE, Potz JL, Rosen PP: **Metastatic Prostate Adenocarcinoma Within a Primary Solid Papillary Carcinoma of NMale Breast- Application of Immunohistochemistry to a Unique Collision Tumour.** *Archives of Pathology & Laboratory Medicine* 2001, **125**:1101-1103.
- Park Y, Oster MW, Olarte MR: **Prostatic cancer with an unusual presentation: polymyositis and mediastinal adenopathy.** *Cancer* 1981, **48**:1262-1264.
- Hayashi S, Hamanaka Y, Sueda T, Yonehara S, Matsuura Y: **Thymic metastasis from prostatic carcinoma: report of a case.** *Surg Today* 1993, **23**:632-634.
- Autorino R, Zito A, Di Giacomo F, Cosentino L, Quarto G, Di Lorenzo G, Mordente S, Pane U, Giordano A, D'Armiento M: **Orbital metastasis as a first indication of prostate cancer: a case report.** *Arch Ital Urol Androl* 2005, **77**:109-110.
- Obek C, Kural AR, Yacyioglu O, Kendiroglu G, Solok V: **Metastatic adenocarcinoma of the prostate to the uvea as the initial presenting symptom in a 49-year-old man.** *Urology* 2001, **58**:106.
- Tsai V, Kim S, Clatterbuck RE, Ewend MG, Olivi A: **Cystic prostate metastases to the brain parenchyma: report of two cases and review of the literature.** *J Neurooncol* 2001, **51**:167-173.
- Papatsoris AG, Mpadra FA, Karamouzis MV: **Prostate cancer presenting as a solitary cerebellar metastasis. A case report and review of the literature.** *Tumori* 2002, **88**:61-64.
- Chevillat JC, Tindall D, Boelter C, Jenkins R, Lohse CM, Pankratz VS, Sebo TJ, Davis B, Blute ML: **Metastatic prostate carcinoma to bone: clinical and pathologic features associated with cancer-specific survival.** *Cancer* 2002, **95**:1028-1036.
- Vaghefi H, Magi-Galluzzi C, Klein EA: **Local recurrence of prostate cancer in rectal submucosa after transrectal needle biopsy and radical prostatectomy.** *Urology* 2005, **66**:881.
- Bowrey DJ, Otter MI, Billings PJ: **Rectal infiltration by prostatic adenocarcinoma: report on six patients and review of the literature.** *Ann R Coll Surg Engl* 2003, **85**:382-385.
- Malhi-Chowla N, Wolfson HC, Menke D, Woodward TA: **Prostate cancer metastasizing to the small bowel.** *J Clin Gastroenterol* 2001, **32**:439-440.
- Culkin DJ, Demos TC, Wheeler JS, Castelli M, Canning JR: **Separate annular strictures of the rectosigmoid colon secondary to unsuspected prostate cancer.** *J Surg Oncol* 1990, **43**:189-192.
- Gengler L, Baer J, Finby N: **Rectal and sigmoid involvement secondary to carcinoma of the prostate.** *Am J Roentgenol Radium Ther Nucl Med* 1975, **125**:910-917.
- Ars c, Duck L, Baurain JF, Moulin P, Duprez T, Machiels JP: **Unusual metastatic features in a patient with concomitant malignant orbital melanoma and prostate carcinoma.** *Journal of Neuro-Oncology* 2004, **66**:361-363.
- Fusi A, Procopio G, Delia Torre S, Ricotta R, Bianchini G, Salvioni R, Ferrari L, Martinetti A, Savelli G, Villa S, Bajetta E: **Treatment options in hormone-refractory metastatic prostate carcinoma.** *Tumori* 2004, **90**:535-546.
- de la Monte SM, Moore GW, Hutchins GM: **Metastatic behavior of prostate cancer. Cluster analysis of patterns with respect to estrogen treatment.** *Cancer* 1986, **58**:985-993.

Publish with **BioMed Central** and every scientist can read your work free of charge

"BioMed Central will be the most significant development for disseminating the results of biomedical research in our lifetime."

Sir Paul Nurse, Cancer Research UK

Your research papers will be:

- available free of charge to the entire biomedical community
- peer reviewed and published immediately upon acceptance
- cited in PubMed and archived on PubMed Central
- yours — you keep the copyright

Submit your manuscript here:  
http://www.biomedcentral.com/info/publishing\_adv.asp

